

Piflufolastat (^{18}F) self-training educational material for healthcare professionals to interpret piflufolastat (^{18}F) PET/CT

This educational material provides with recommendations to reduce and prevent misinterpretation risks from the use of piflufolastat (^{18}F). Additional information regarding piflufolastat (^{18}F) is available in the Summary of Product Characteristics (SmPC) and package leaflet (PIL) on the Health Agency website.

SUMMARY

1 Important information

2 Prostate Specific Membrane Antigen (PSMA)

3 EANM Guidelines on PSMA-ligand PET/CT

4 Piflufolastat (^{18}F) PET/CT

4.1 Chemical structure of piflufolastat (^{18}F)

4.2 Indications

4.3 Patient preparation, dosing

4.4 Acquisition

4.5 Physiological distribution and dosimetry

4.6 Interpretation

5 Case reports

5.1 Initial staging, biochemical recurrence, false positive findings, false negative findings, incidental findings

5.2 Self testing

CHAPTER 1

Important information

▼ *Piflufolastat (¹⁸F) is subject to additional monitoring.*

This will allow quick identification of new safety information. Healthcare professionals are asked to report any suspected adverse reactions.

Reporting of suspected adverse reactions

Reporting suspected adverse reactions after authorisation of the medicinal product is important. It allows continued monitoring of the benefit/risk balance of the medicinal product. Healthcare professionals are asked to report any suspected adverse reactions to:

Fimea

Lääkealan turvallisuus-ja kehittämiskeskus Fimea

Lääkkeiden haittavaikutusrekisteri

PL 55

00034 FIMEA

www.fimea.fi

Purpose of the training

The purpose of the training is to help you familiarize yourself with the use of piflufolastat (^{18}F) and ensure correct and reliable interpretation of piflufolastat (^{18}F) PET/CT.

This training program is part of the Risk Management Plan (RMP) of piflufolastat (^{18}F).

The accurate and timely acquisition and interpretation of piflufolastat (^{18}F) PET/CT are the responsibility of the nuclear medicine physician at the PET/CT center.

Piflufolastat (^{18}F) PET/CT should only be interpreted by trained nuclear medicine physician.

Training in the interpretation of piflufolastat (^{18}F) PET/CT, including suggested interpretation criteria presented on the following slides, is not intended to replace the independent medical judgment of the physician responsible for the management of each patient and is not a guarantee of specific clinical outcomes.

CHAPTER 2

Prostate Specific Membrane Antigen (PSMA)

PSMA is a type II transmembrane protein with an extracellular binding site that is internalized after ligand binding.

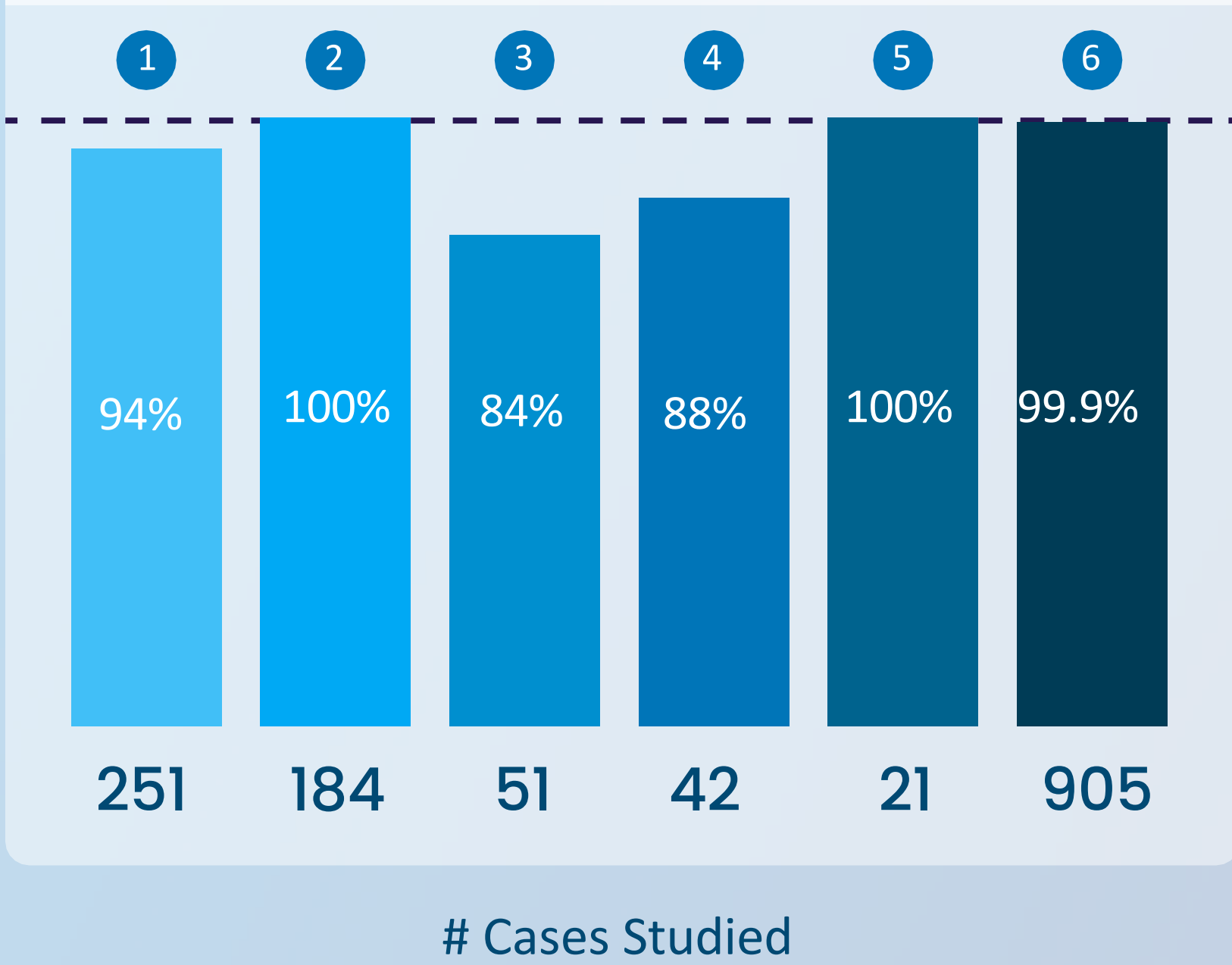
PSMA tissue expression is high on the cell surface of prostatic tissues including prostate cancer.

Despite the name, PSMA is not specific to prostate tissue. The PSMA protein can be found in low concentrations in many other organs.

Prostate Specific Membrane Antigen (PSMA)

PSMA is overexpressed in app. 95% of primary and metastatic lesions in patients with prostate cancer.

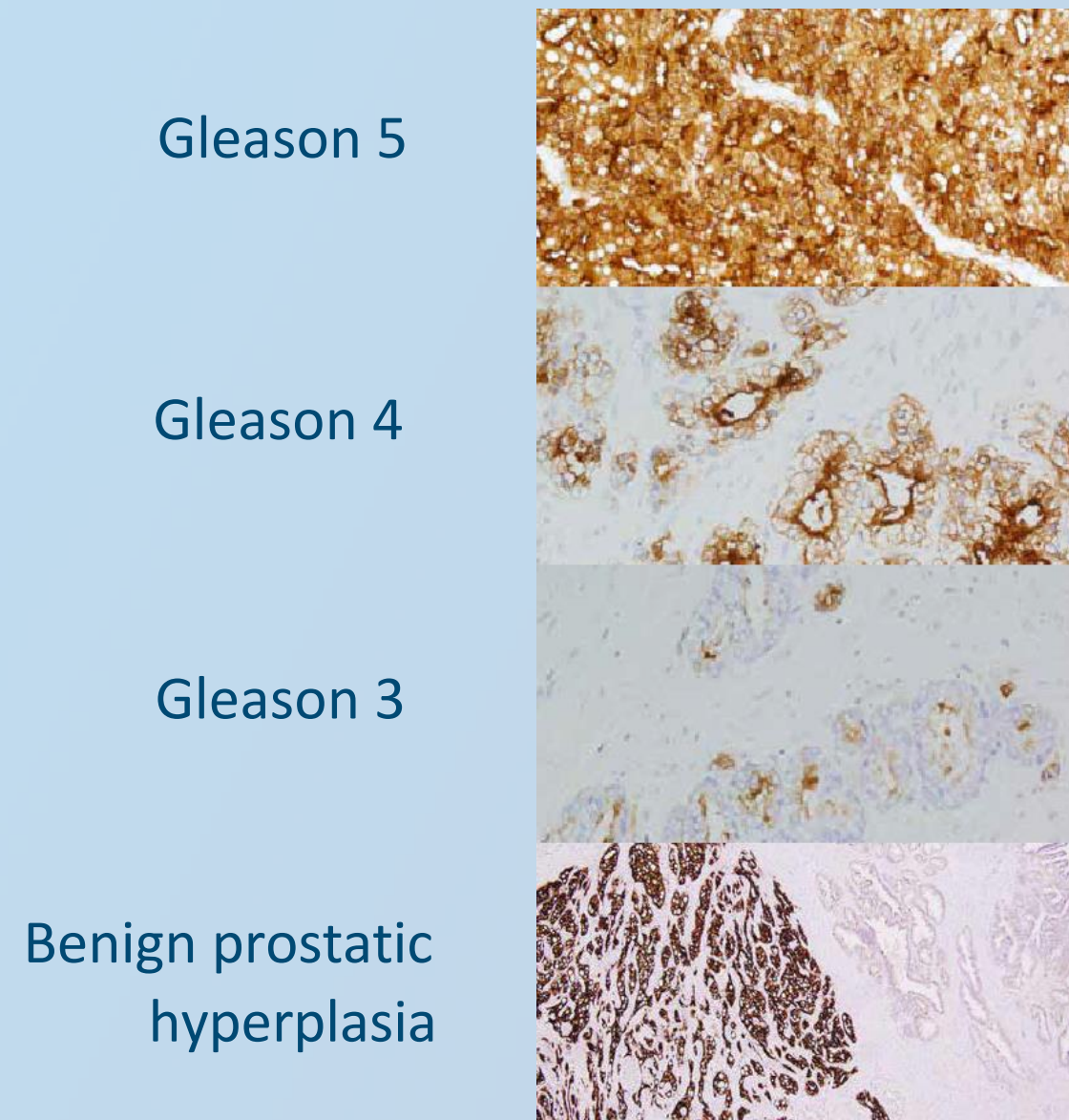
% Cases Reported to be PSMA Positive



- 1 Wright, G. L. et al. (1995) 'Expression of prostate-specific membrane antigen in normal, benign, and malignant prostate tissues', *Urologic Oncology*, 1(1), pp. 18–28.
- 2 Bostwick, D. G. et al. (1998) 'Prostate specific membrane antigen expression in prostatic intraepithelial neoplasia and adenocarcinoma: a study of 184 cases', *Cancer*, 82(11), pp. 2256–2261.
- 3 Mannweiler, S. et al. (2009) 'Heterogeneity of prostate-specific membrane antigen (PSMA) expression in prostate carcinoma with distant metastasis', *Pathology oncology research: POR*, 15(2), pp. 167–172.
- 4 Kusumi, T. et al. (2008) 'Immunohistochemical detection of carcinoma in radical prostatectomy specimens following hormone therapy', *Pathology International*, 58(11), pp. 687–694.
- 5 Ananias, H. J. K. et al. (2009) 'Expression of the gastrin-releasing peptide receptor, the prostate stem cell antigen and the prostate-specific membrane antigen in lymph node and bone metastases of prostate cancer', *The Prostate*, 69(10), pp. 1101–1108.
- 6 Kasperzyk, J. L. et al. (2013) 'Prostate-specific membrane antigen protein expression in tumor tissue and risk of lethal prostate cancer', *Cancer Epidemiology, Biomarkers & Prevention: A Publication of the American Association for Cancer Research*, Cosponsored by the American Society of Preventive Oncology, 22(12), pp. 2354–2363.

Prostate Specific Membrane Antigen (PSMA)

PSMA expression is increasing with histologic grade.



ISUP 5 = Gleason 9 or 10

ISUP 4 = Gleason 8

ISUP 3 = Gleason 7

ISUP 2 = Gleason 7

ISUP 1 = Gleason ≤6

4+5, 5+4, 5+5
4+4, 3+5, 5+3
4+3
3+4
≤3+3

Courtesy of Dr. Neil Bander, New York-Presbyterian Hospital, Dr Frederik Giesel, University of Heidelberg
<https://radiopaedia.org/cases/isup-prostate-cancer-grade-groups-table-1>
<https://radiologyassistant.nl/abdomen/prostate/prostate-cancer-pi-rads-v2-1>

CHAPTER 3

EANM Guidelines on PSMA-ligand PET/CT

Provide with guidance on:

- Indications for PSMA-ligand PET/CT
- Potential clinical applications of PSMA-ligand PET/CT
- Procedure and specification of the examination
- PSMA-ligand PET/CT acquisition protocol
- Normal biodistribution and dosimetry of PSMA ligands
- Important pitfalls of imaging with PSMA-ligands
- The standardised structured reporting system in staging, recurrent setting, advanced setting, and evaluation of therapeutic response

CHAPTER 4

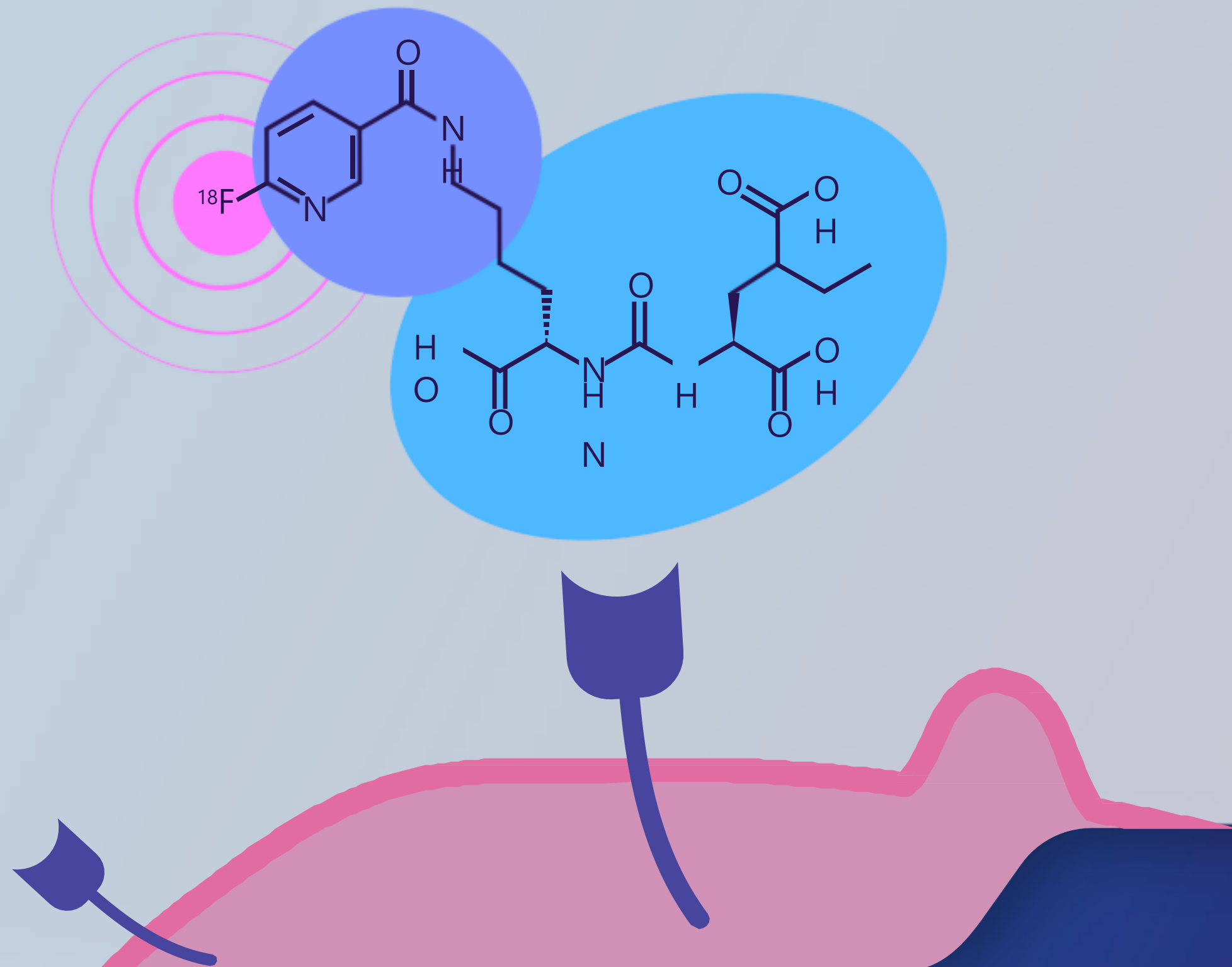
Piflufolastat (^{18}F) PET/CT

4.1

Chemical structure of piflufolastat (^{18}F)

Chemical structure of piflufolastat (^{18}F)

2-(3-{1-carboxy-5-[(6- ^{18}F]fluoro-pyridine-3-carbonyl)-amino]-pentyl}-ureido)-pentanedioic acid



4.2

Piflufolastat (^{18}F): Indications

Piflufolastat (¹⁸F): Indications

Piflufolastat (¹⁸F) is indicated for the detection of prostate-specific membrane antigen (PSMA) positive lesions with positron emission tomography (PET) in adults with prostate cancer. Which clinical settings ?

- 1** Primary staging of patients with high-risk prostate cancer prior to initial curative therapy.
- 2** To localize recurrence of prostate cancer in patients with a suspected recurrence based on increasing serum PSA levels after primary treatment with curative intent.

4.3

Piflufolastat (^{18}F):

Patient preparation, posology

Piflufolastat (¹⁸F): Patient preparation, posology

- No fasting requirement prior to the injection.
- Encourage patient to drink enough water prior to injection.
- Ongoing medications may be taken prior to injection.
- The mean recommended activity of piflufolastat (¹⁸F) is 4 MBq/kg of body weight and can vary from 3 to 5 MBq/kg of body weight depending on the PET equipment and acquisition mode used.
- The minimum activity should not fall below 190 MBq and the maximum activity should not exceed 360 MBq.
- Bolus administration via an intravenous flexible catheter, followed by a flush of 5-10 mL sodium chloride 9 mg/mL (0.9%) solution for injection.
- Acquisition should be started 90 min to 120 min after the injection of piflufolastat (¹⁸F).
- Advise the patient to void immediately prior to acquisition.

4.4

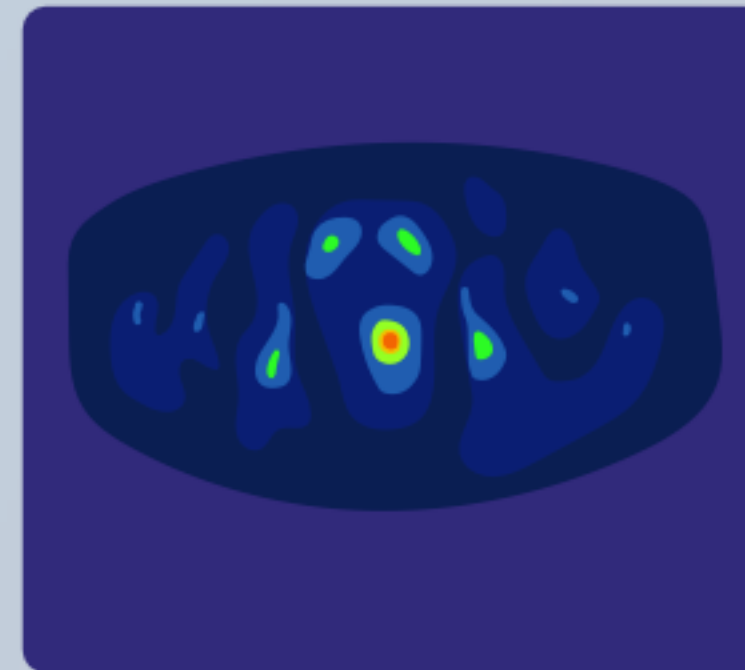
Piflufolastat (^{18}F) PET/CT: Acquisition

Piflufolastat (^{18}F) PET/CT: Acquisition

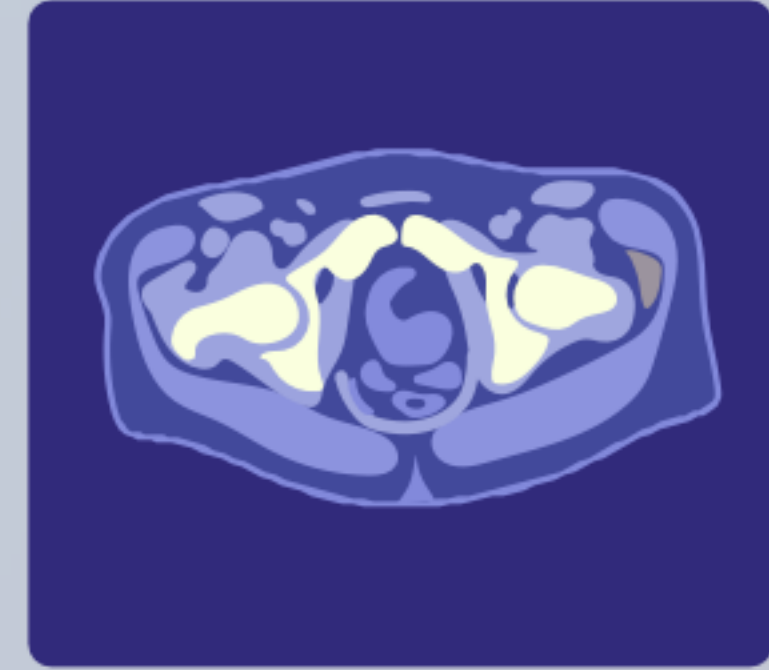
A non-contrast enhanced low-dose CT scan is performed for attenuation correction and anatomic correlation, from the skull vertex to mid-thigh.

PET is performed from mid-thigh to the skull vertex.

PET



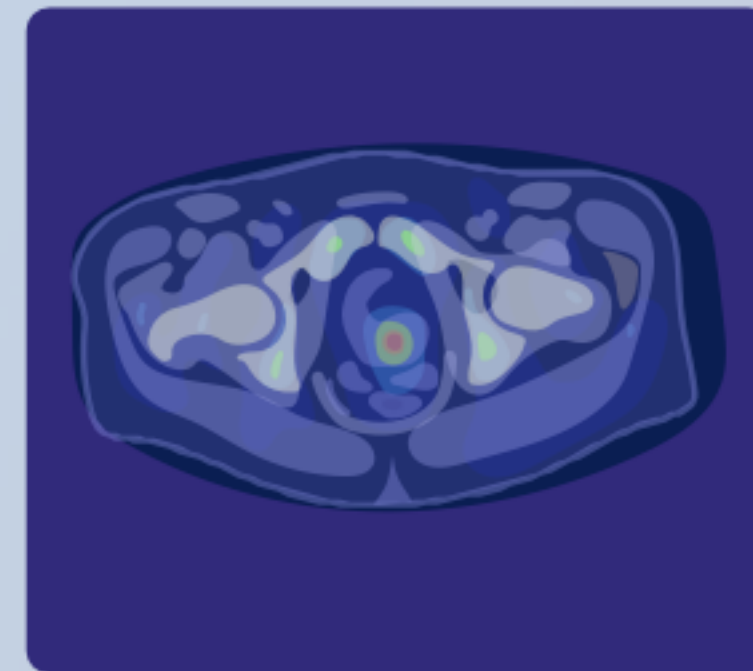
CT



Piflufolastat (^{18}F) PET/CT: Acquisition

When these two scans are fused together, we can view metabolic changes in the proper anatomical context

PET/CT



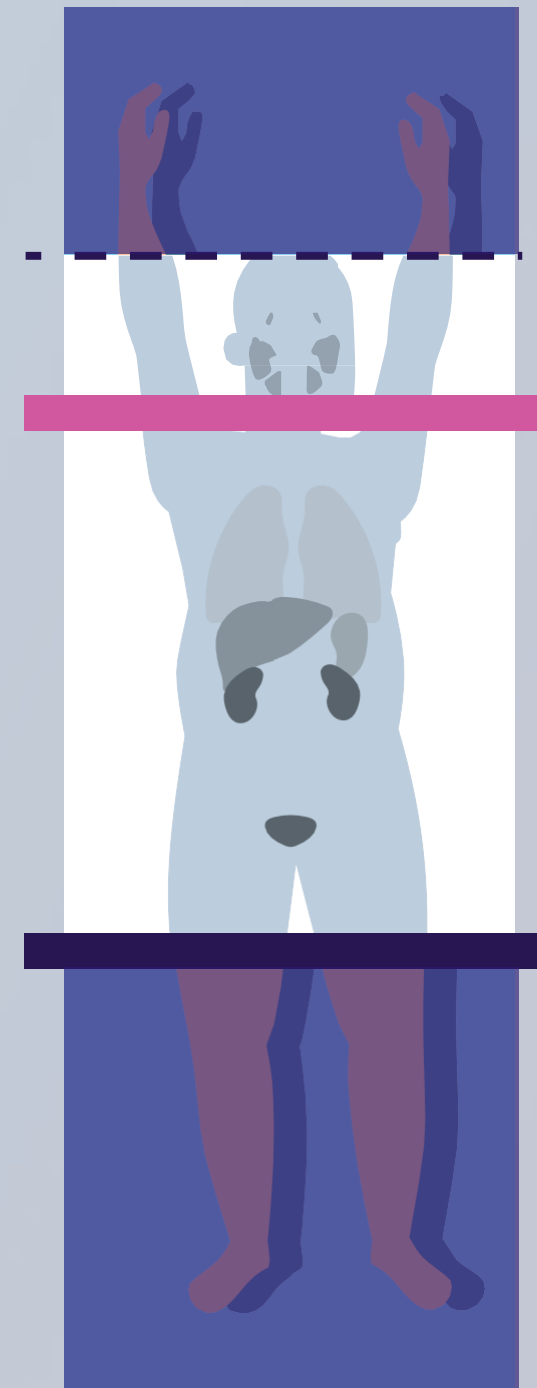Piflufolastat (^{18}F) PET/CT: Acquisition

Patient should be positioned supine with both arms elevated above the head to avoid artefacts.

Acquisition duration is 12 to 40 minutes depending on the type of PET/CT cameras, number of bed positions (typically 6 to 8) and acquisition time per bed position (typically 2 to 5 minutes).

Late acquisitions can also be performed, thus reducing background activity.

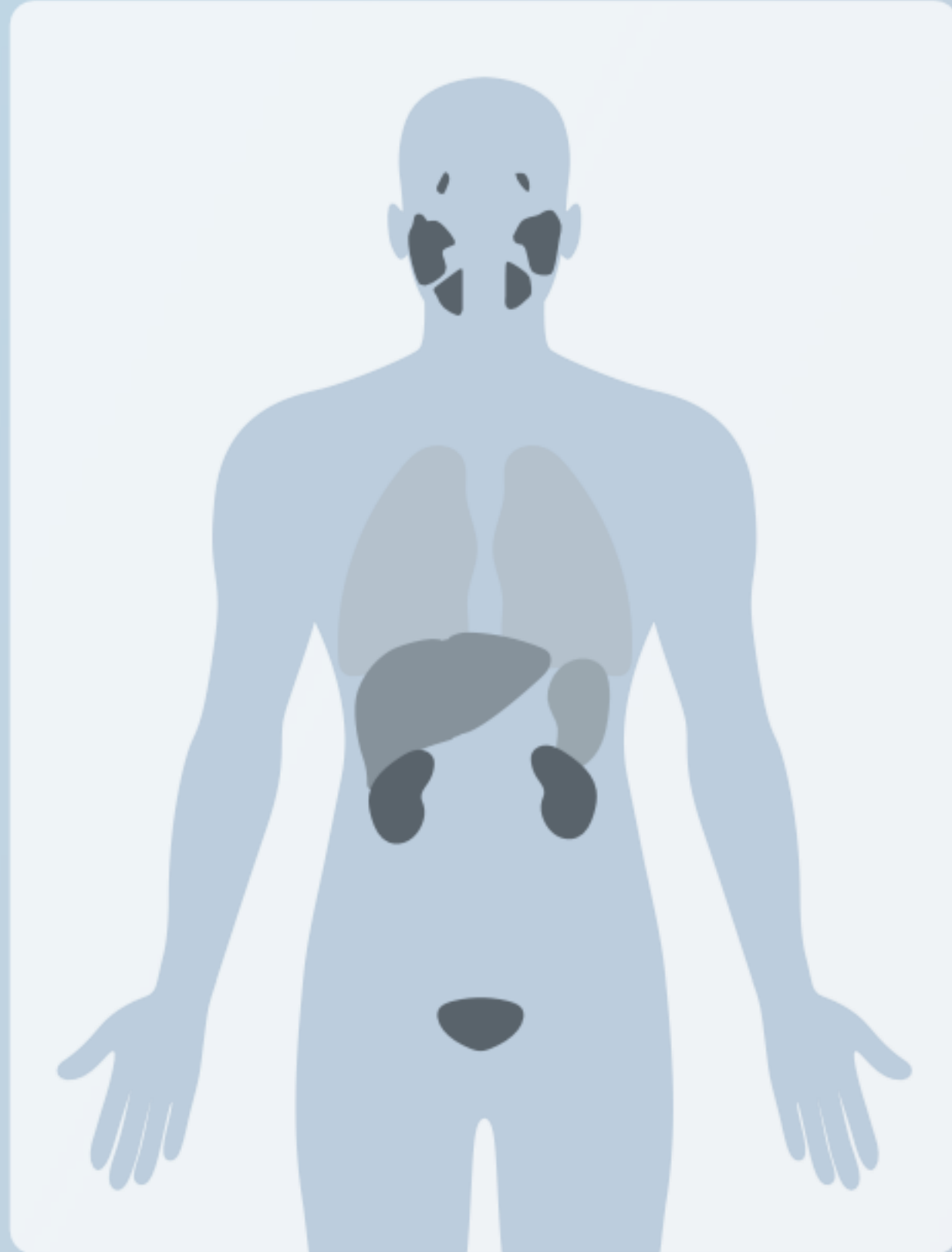Instruct patients to drink and void frequently for the first few hours following piflufolastat (^{18}F) administration.



4.5

Physiological distribution and dosimetry

Piflufolastat (^{18}F): Physiological distribution

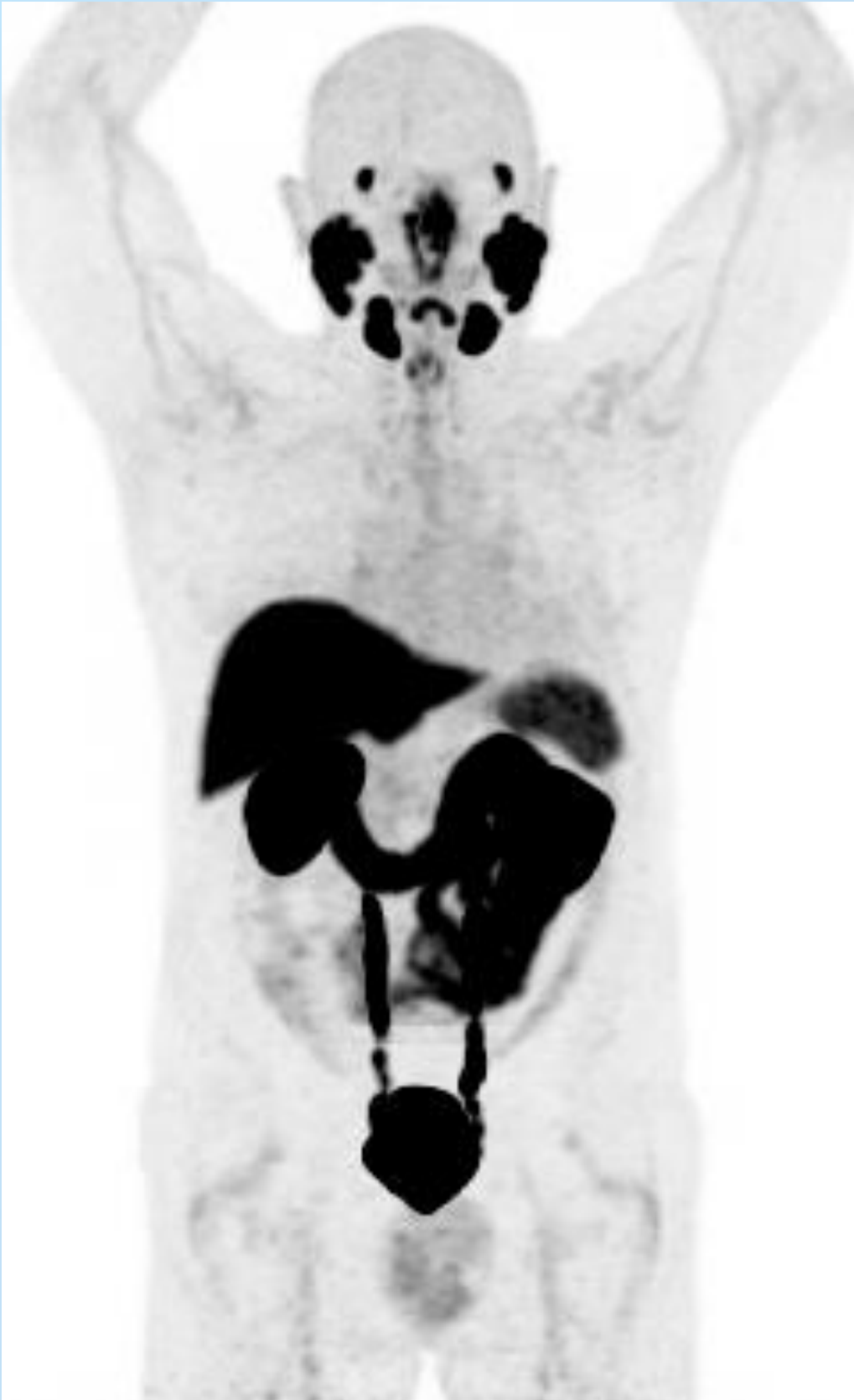

60 min after the injection,
the administered activity is:

- 16.5% in kidneys.
- 9.3% in liver.
- 2.9% in lungs.

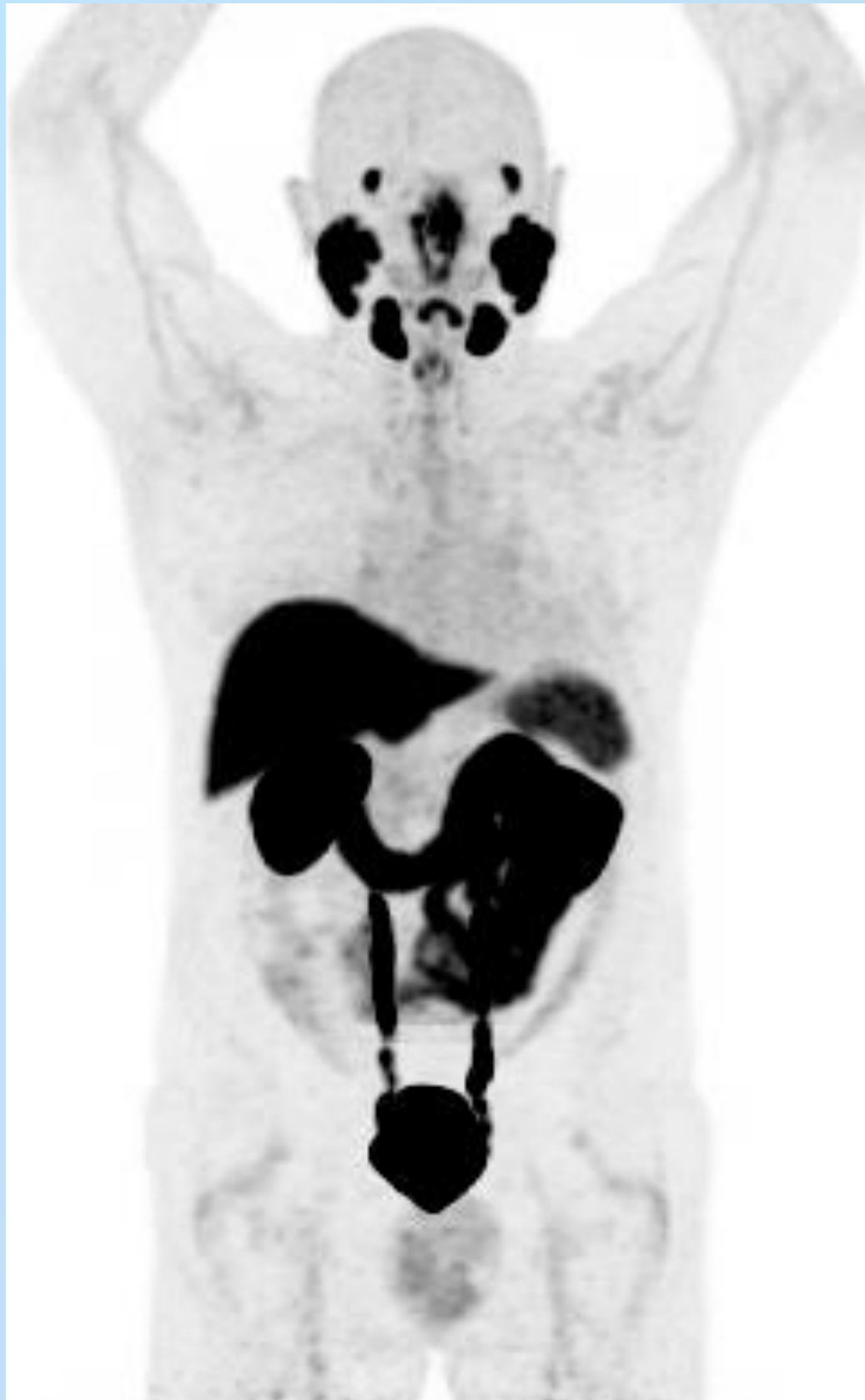8 hours after the injection, approximately 50% of
administered activity is excreted in the urine.

Piflufolastat (^{18}F): Physiological distribution

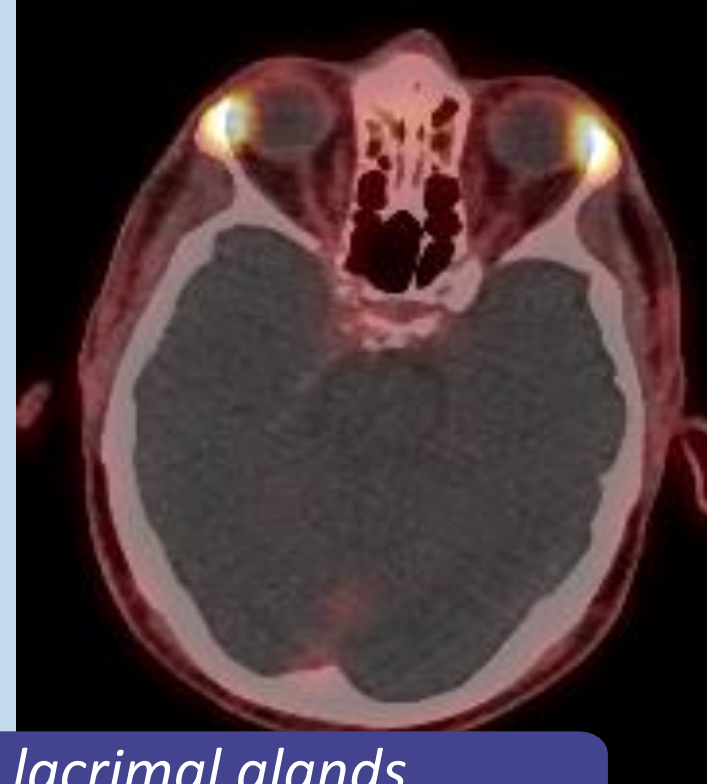


- Piflufolastat (^{18}F) accumulates in healthy tissue where the density of PSMA is high including the:
 - ✓ Lacrimal glands
 - ✓ Salivary glands
 - ✓ Liver
 - ✓ Spleen
 - ✓ Kidneys
- Healthy organs demonstrate significant variability in the uptake of piflufolastat (^{18}F)
- The expression of PSMA can predominantly be found in prostate cancer but can also be observed in other neoplasms (e.g. renal cell carcinoma, hepatocarcinoma, breast cancer, lung cancer and other malignancies) or non-malignant conditions (e.g. hemangioma, ganglia, since they can mimic lymph nodes, benign bone disease as Paget's disease, or pulmonary sarcoidosis/granulomatosis)
- In patients with metastatic disease the impact of tumor burden on healthy organ/tissue uptake is minimal and unlikely to be clinically significant.

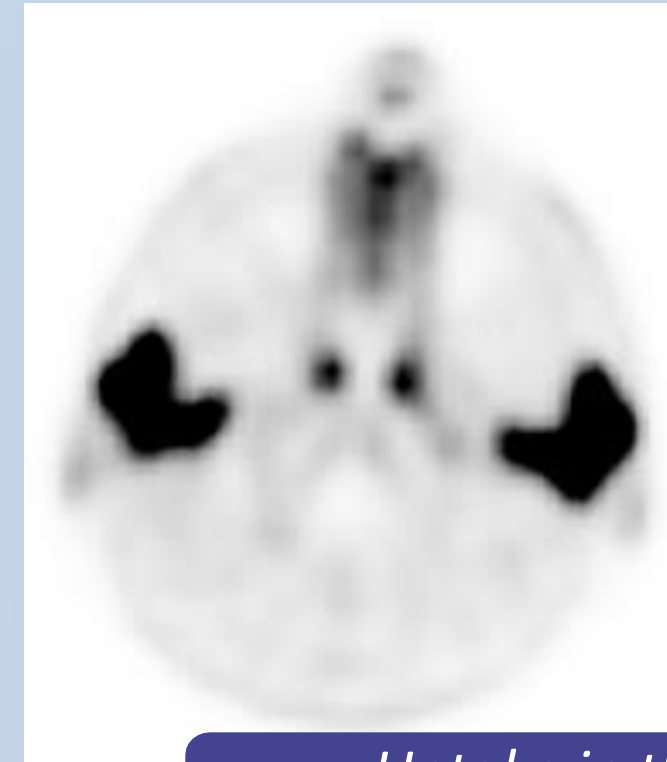
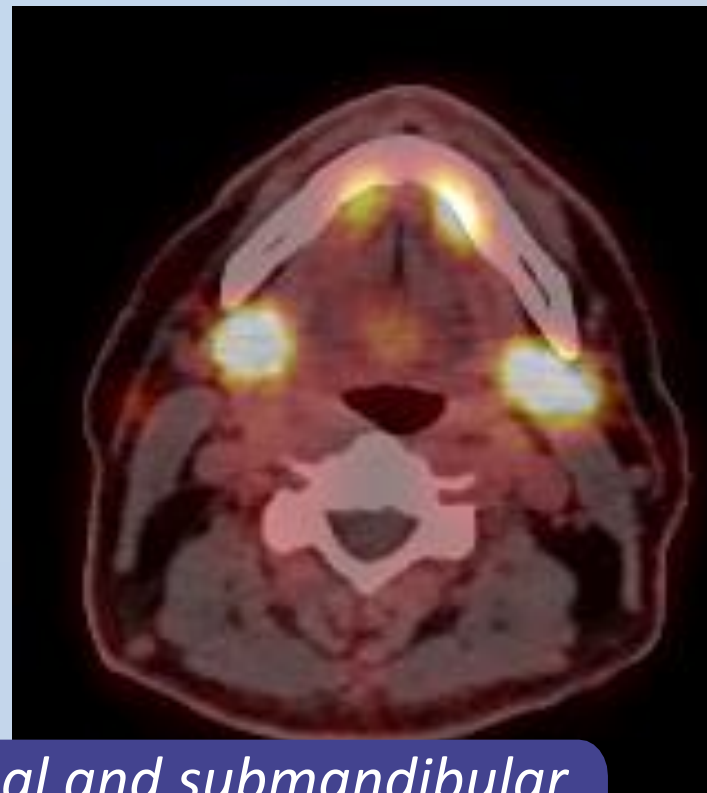
Piflufolastat (^{18}F): Physiological distribution in the area of head and neck



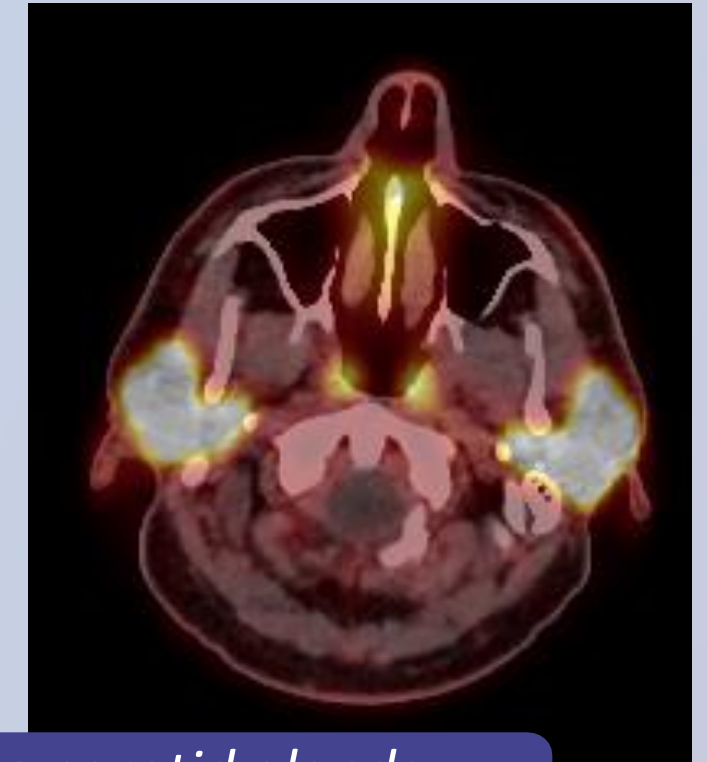
Uptake in the lacrimal glands



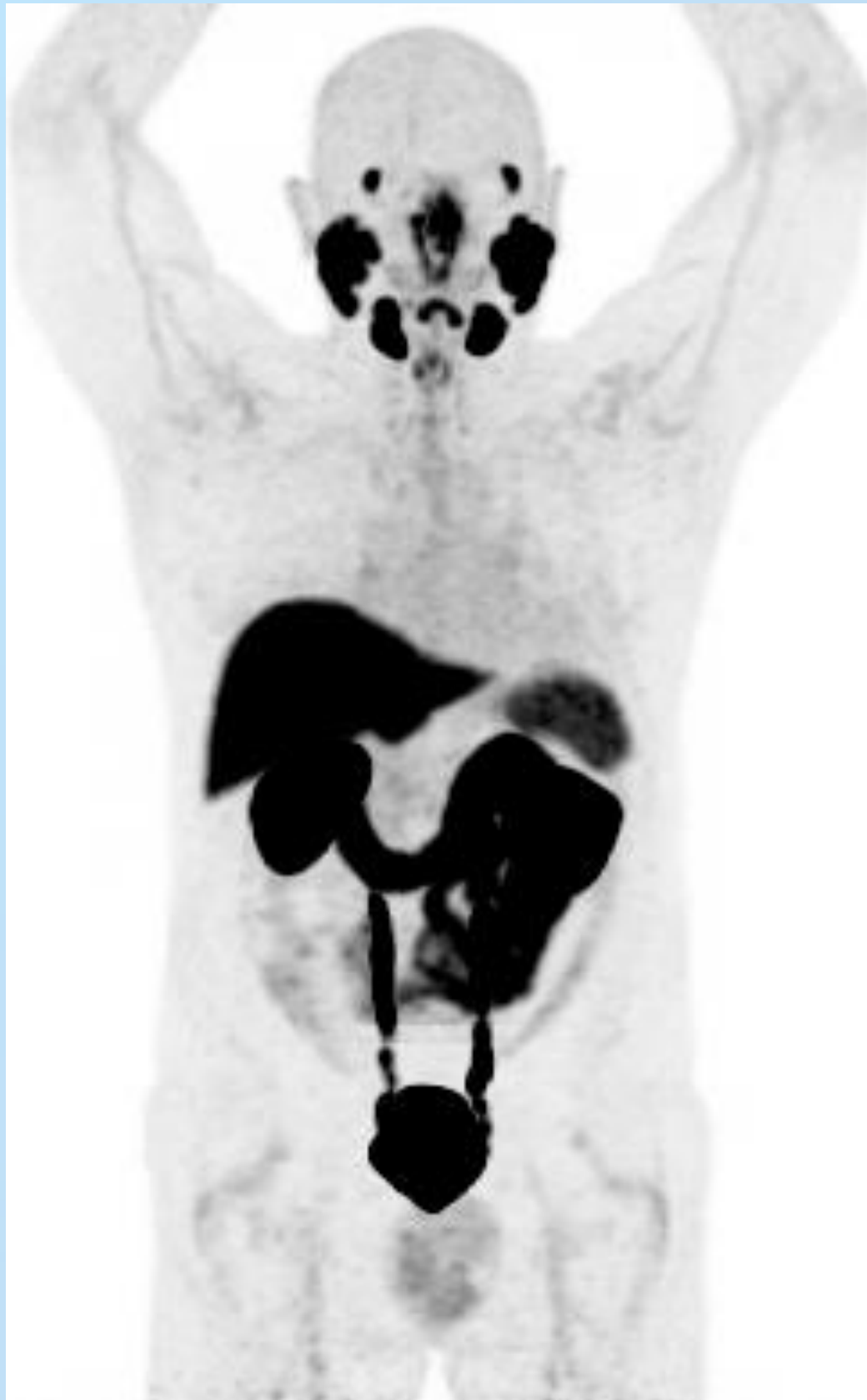Uptake in the sublingual and submandibular salivary glands



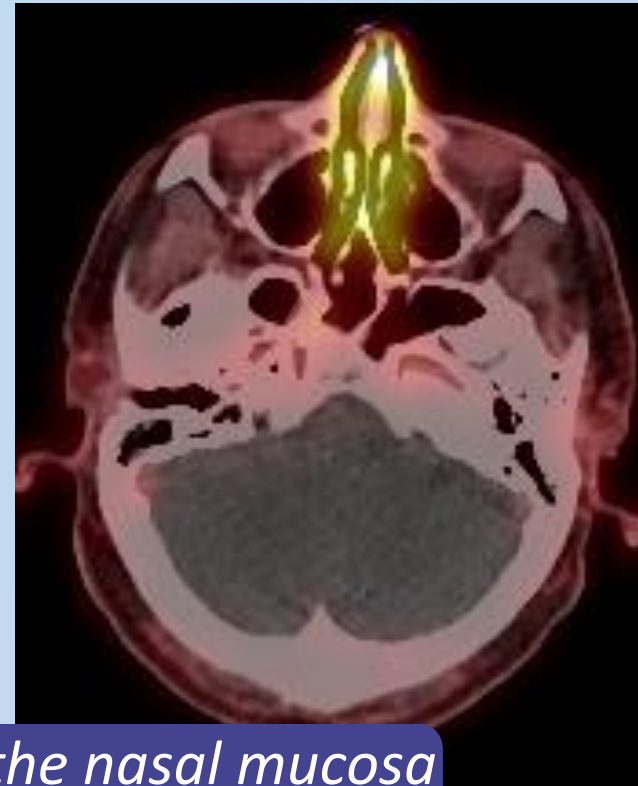Uptake in the parotid glands



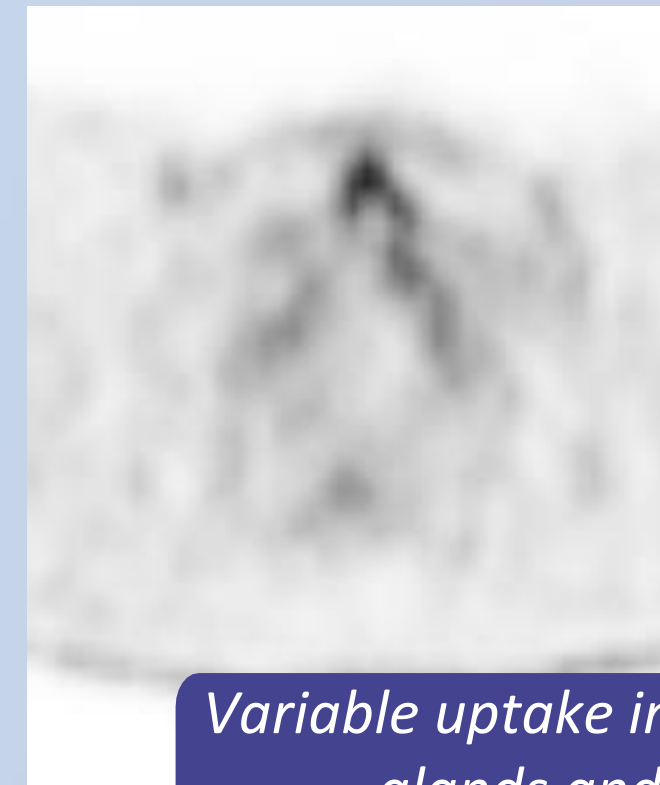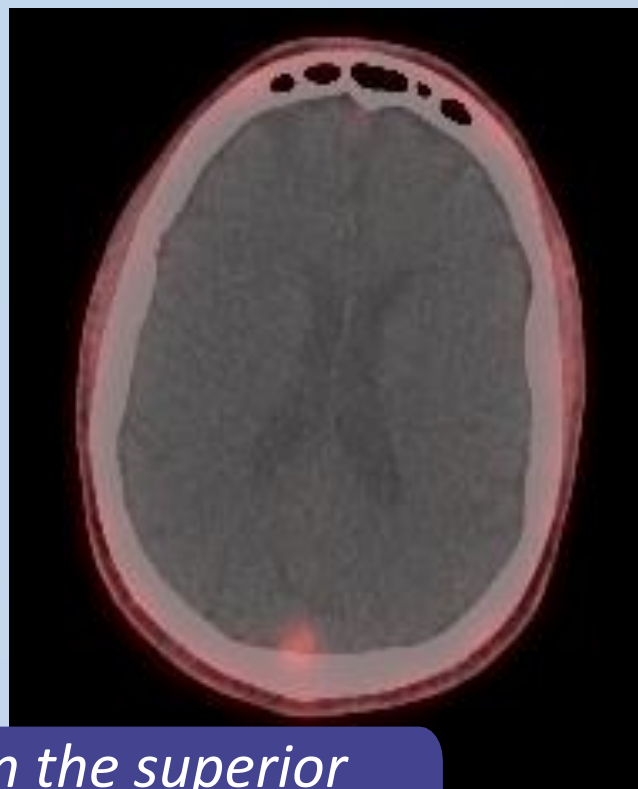
Piflufolastat (^{18}F): Physiological distribution in the area of the head and neck



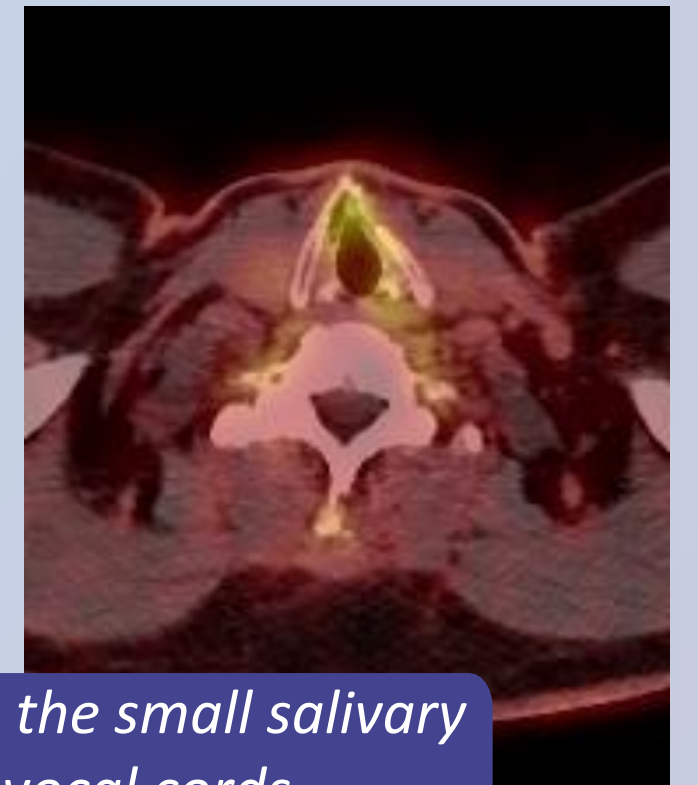Variable uptake in the nasal mucosa



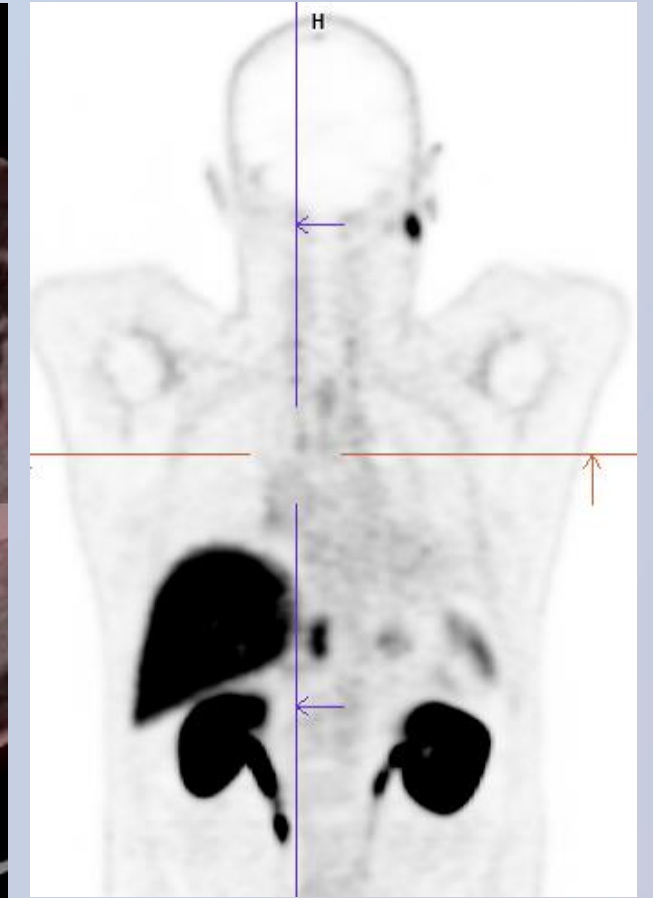
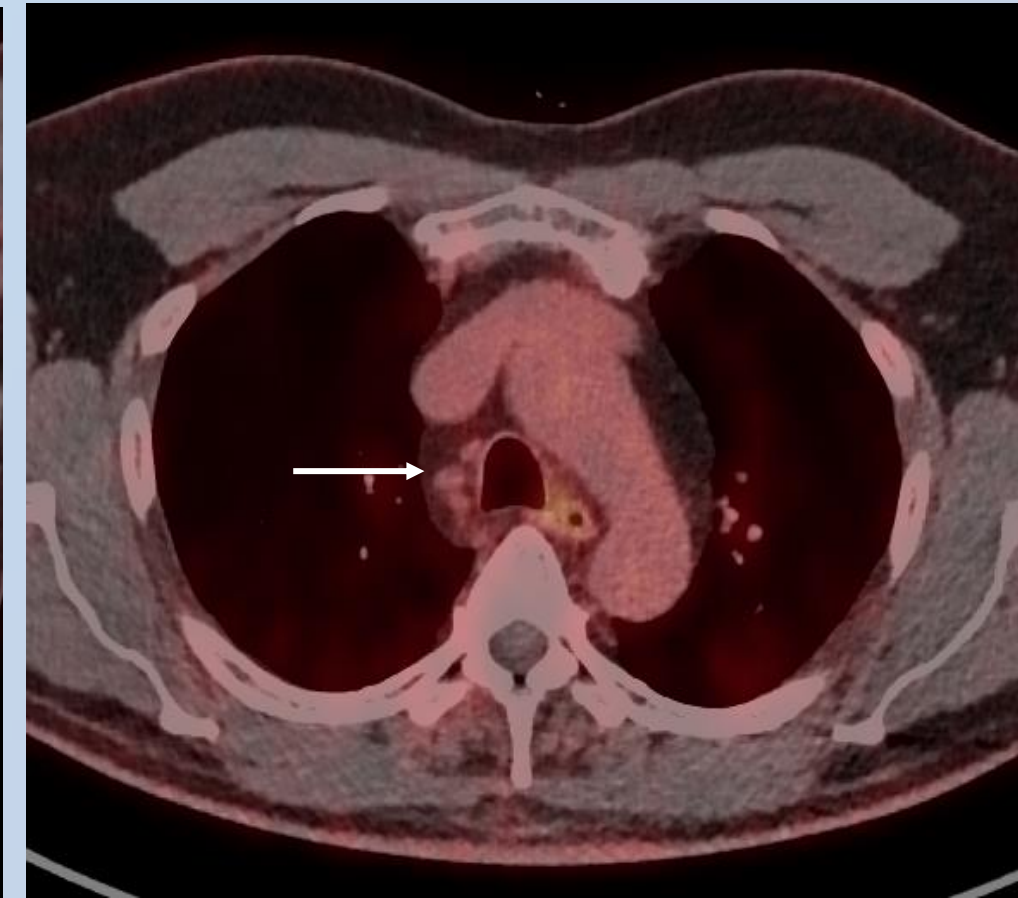
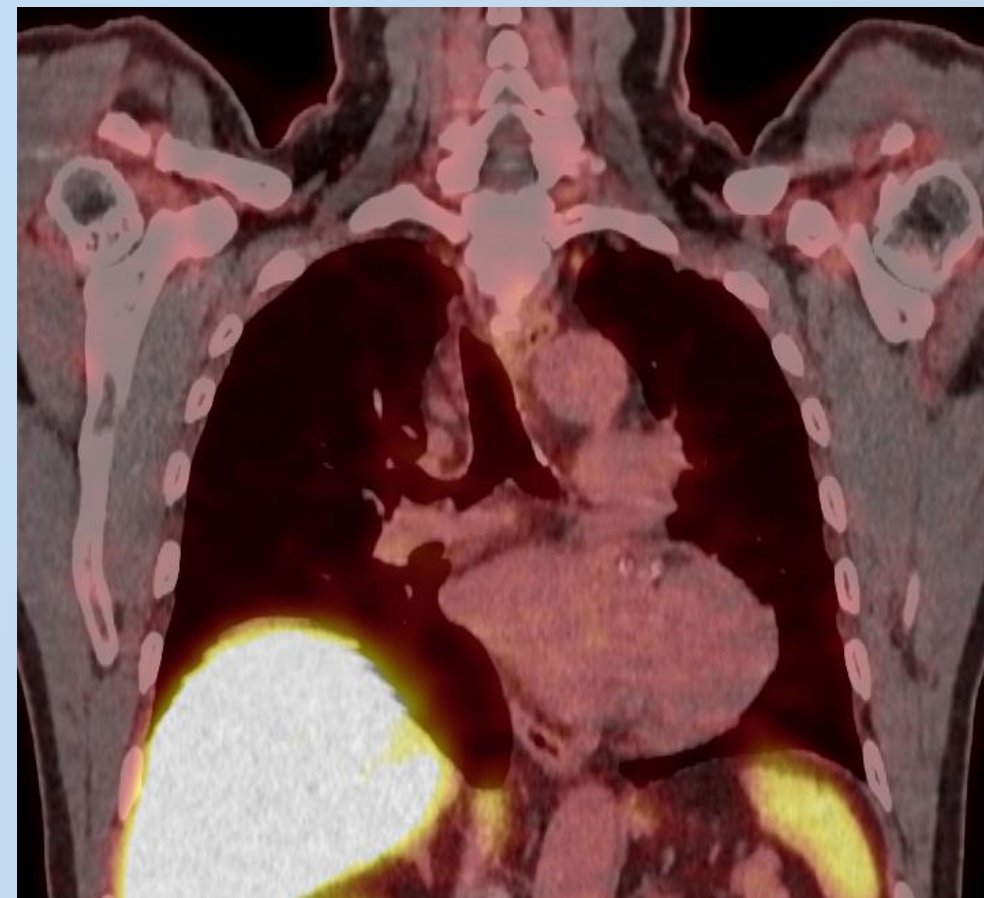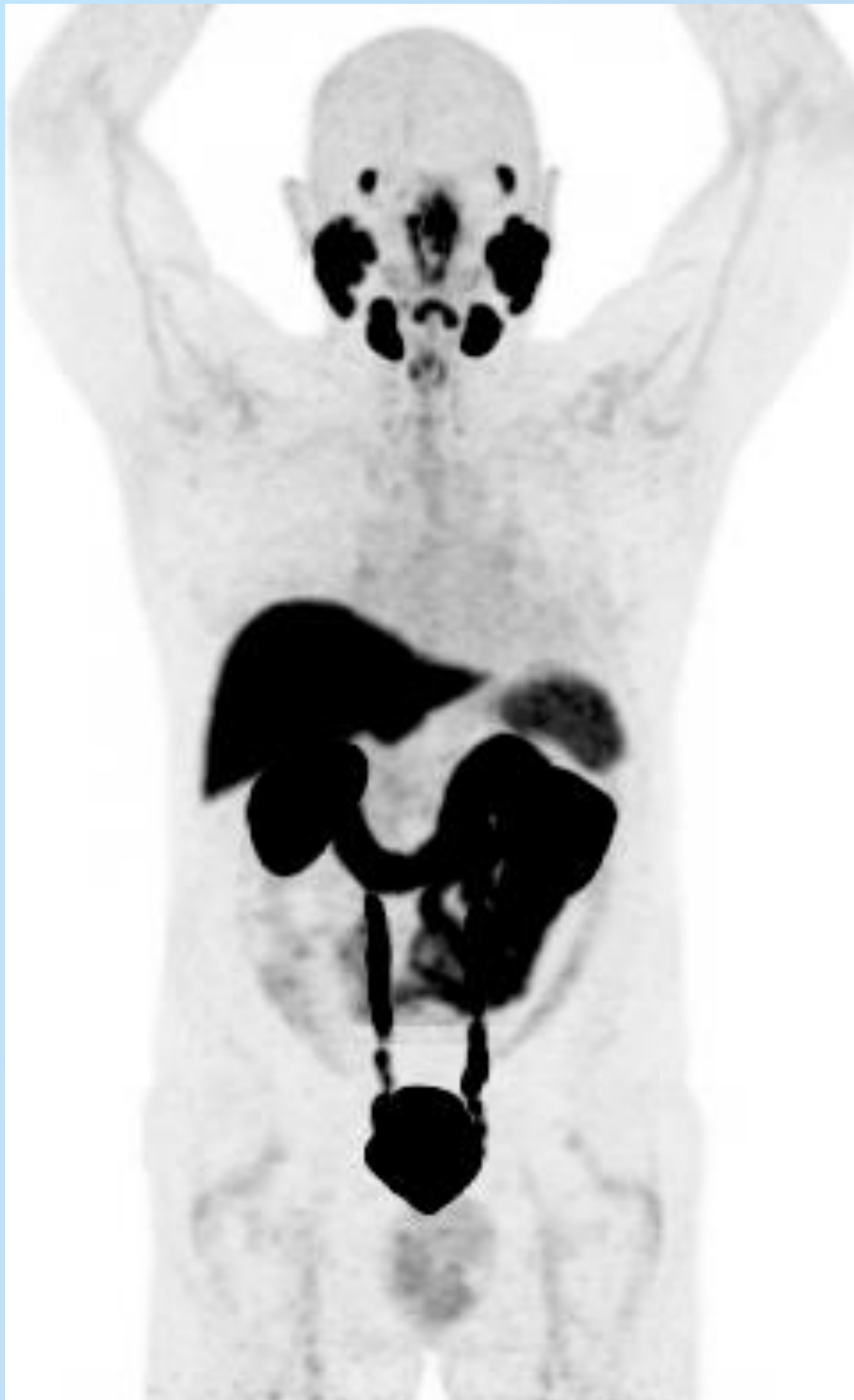Variable uptake in the superior sagittal sinus



Variable uptake in the small salivary glands and vocal cords

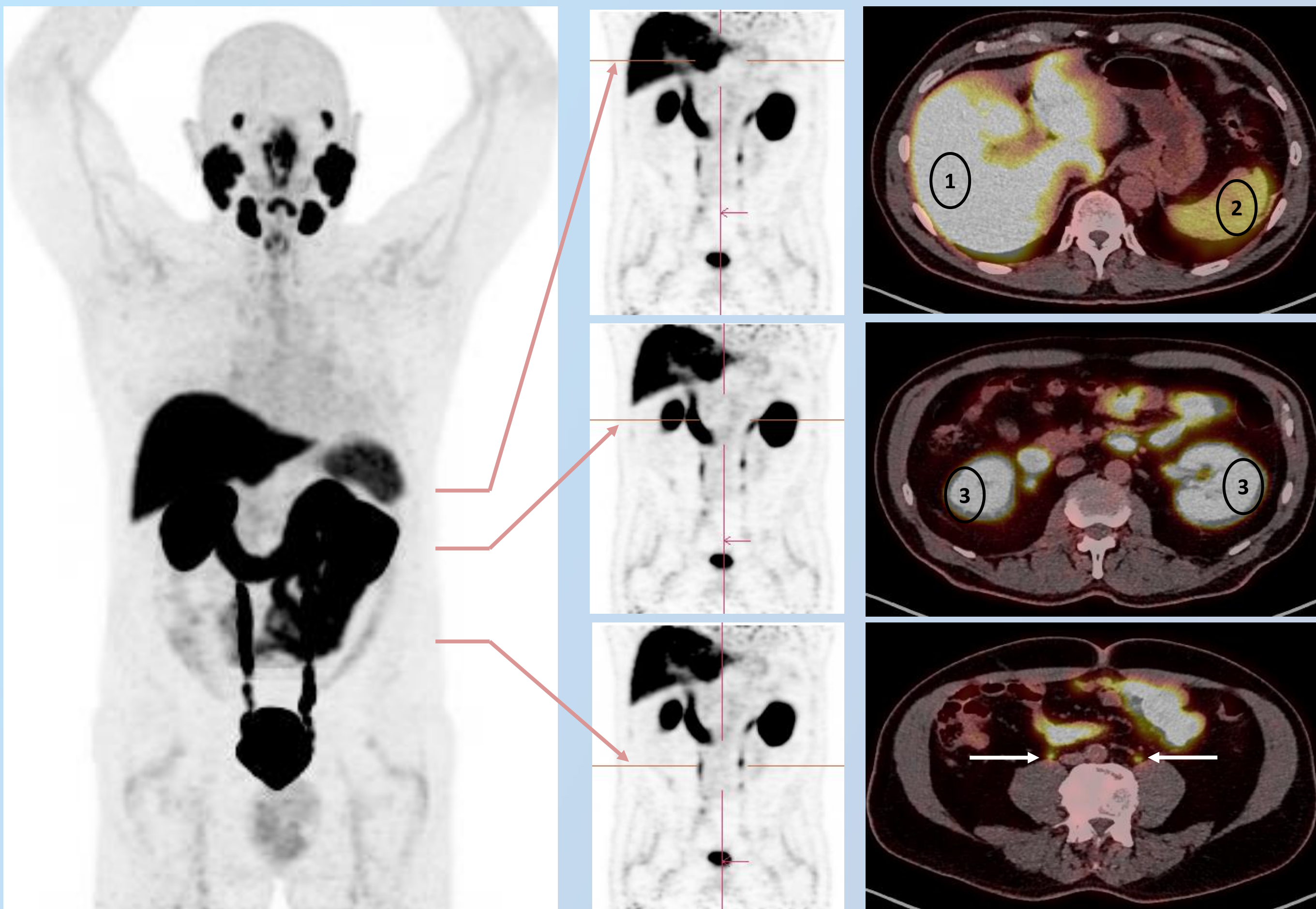


Piflufolastat (^{18}F): Physiological distribution in the thoracic area



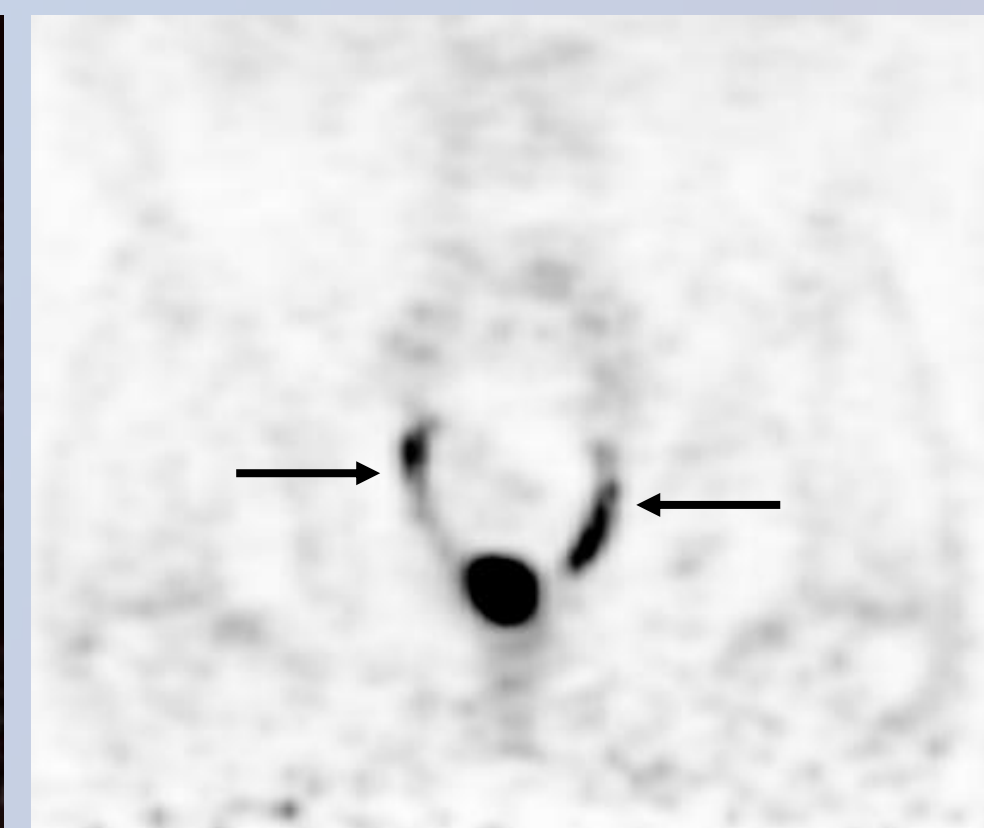
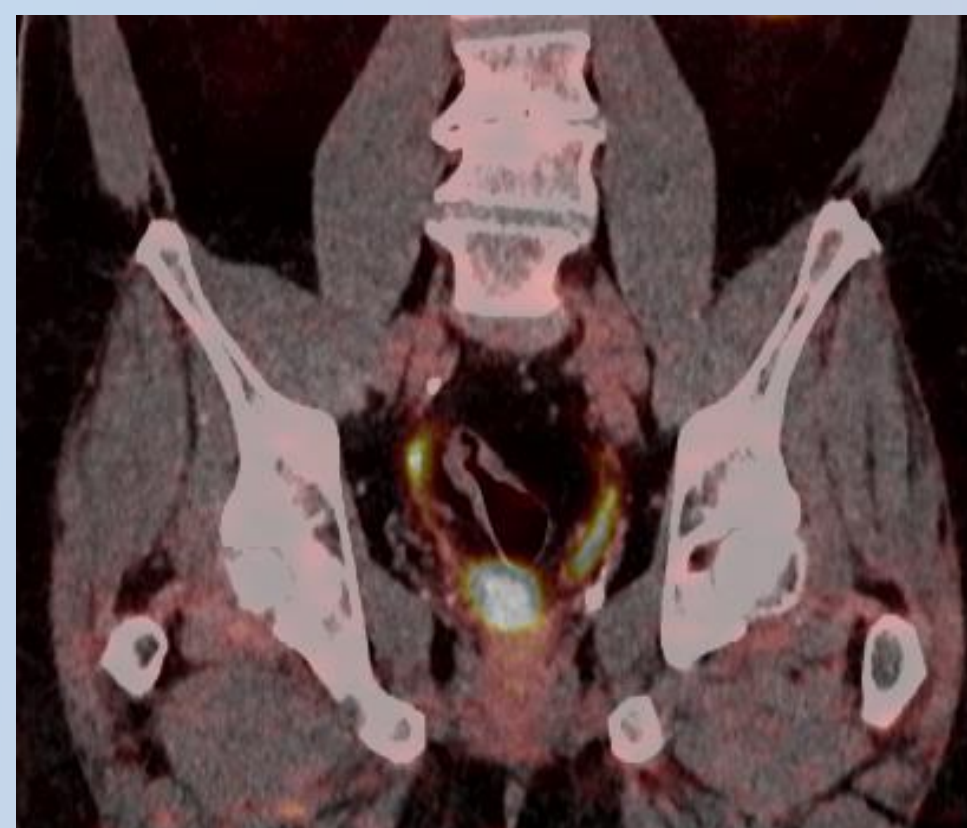
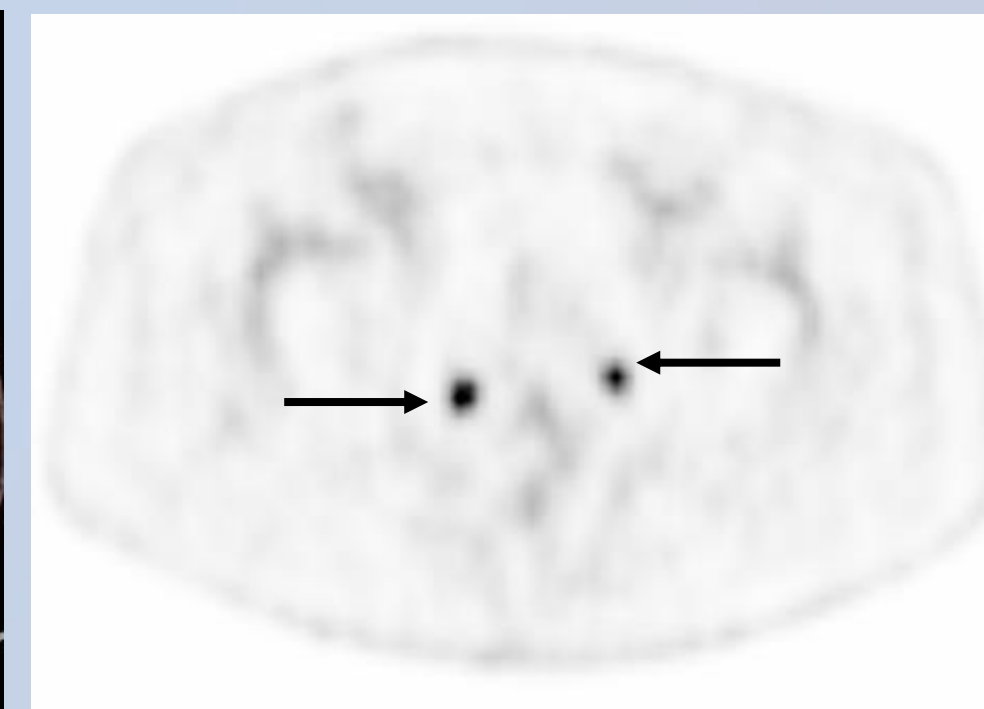
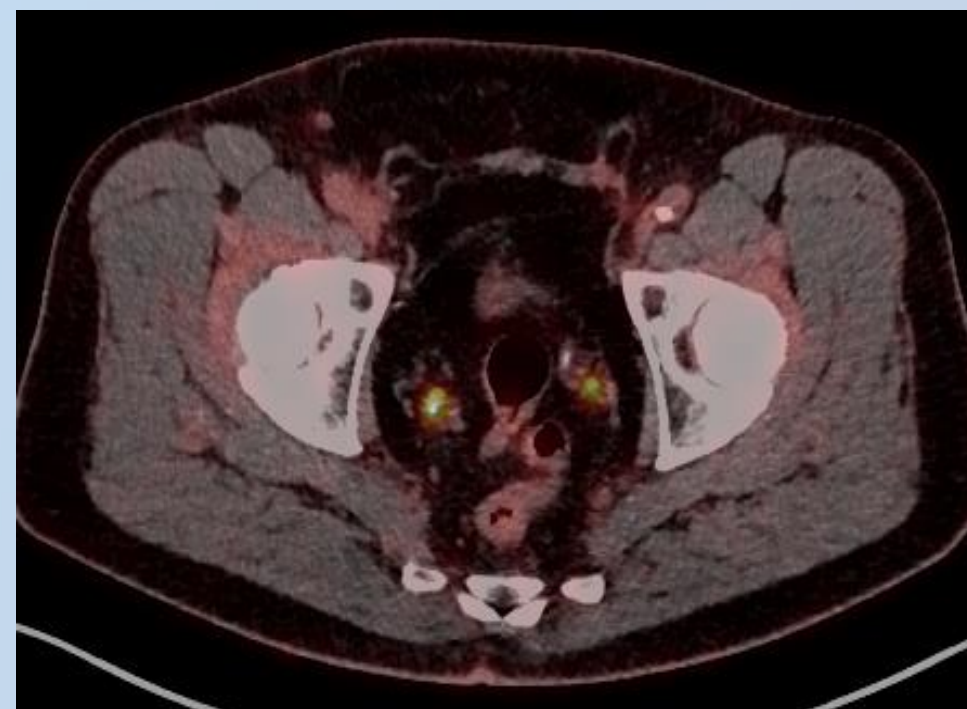
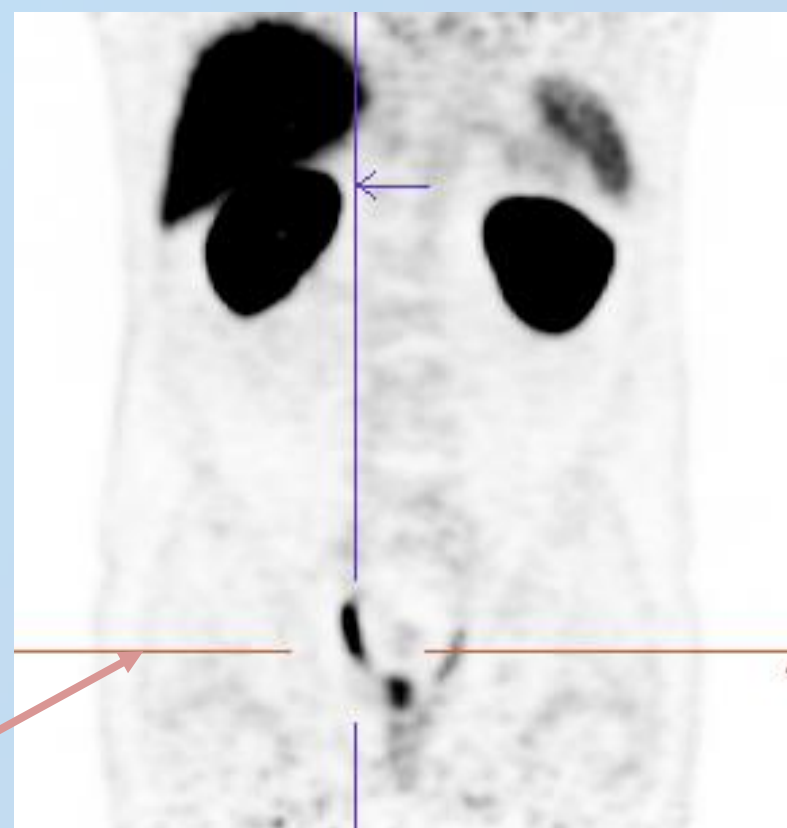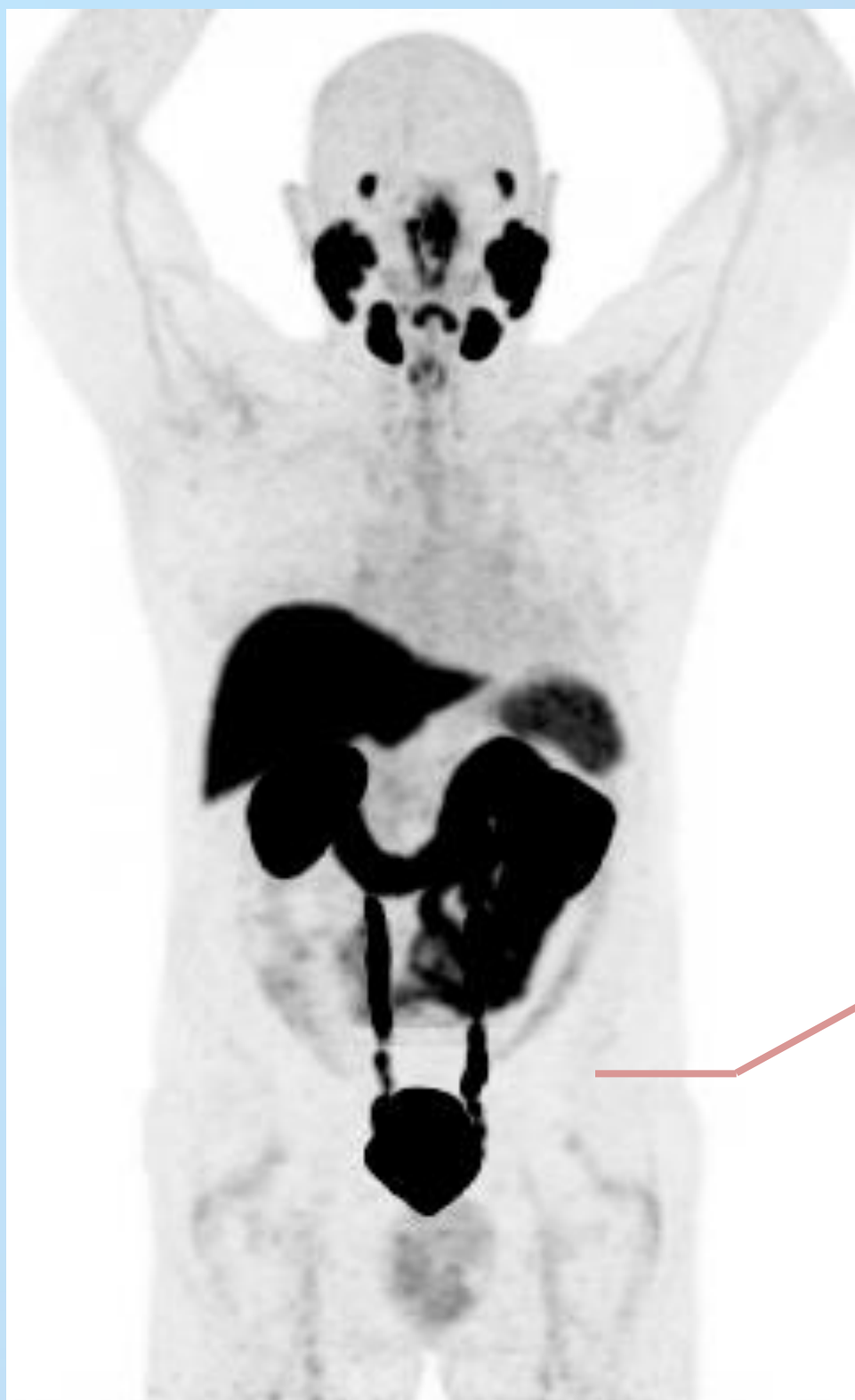
- *No pathological organ or tissue uptake*
- *Possible mild variable uptake by mediastinal and/or hilar lymph nodes*

Piflufolastat (^{18}F): Physiological distribution in the abdominal area



- Uptake in the
 - ✓ 1. Liver
 - ✓ 2. Spleen
 - ✓ 3. Kidneys
- Urinary elimination: activity in the ureters (arrow)
- Activity in the ureters must be distinguished from eventual metastatic retroperitoneal lymph nodes

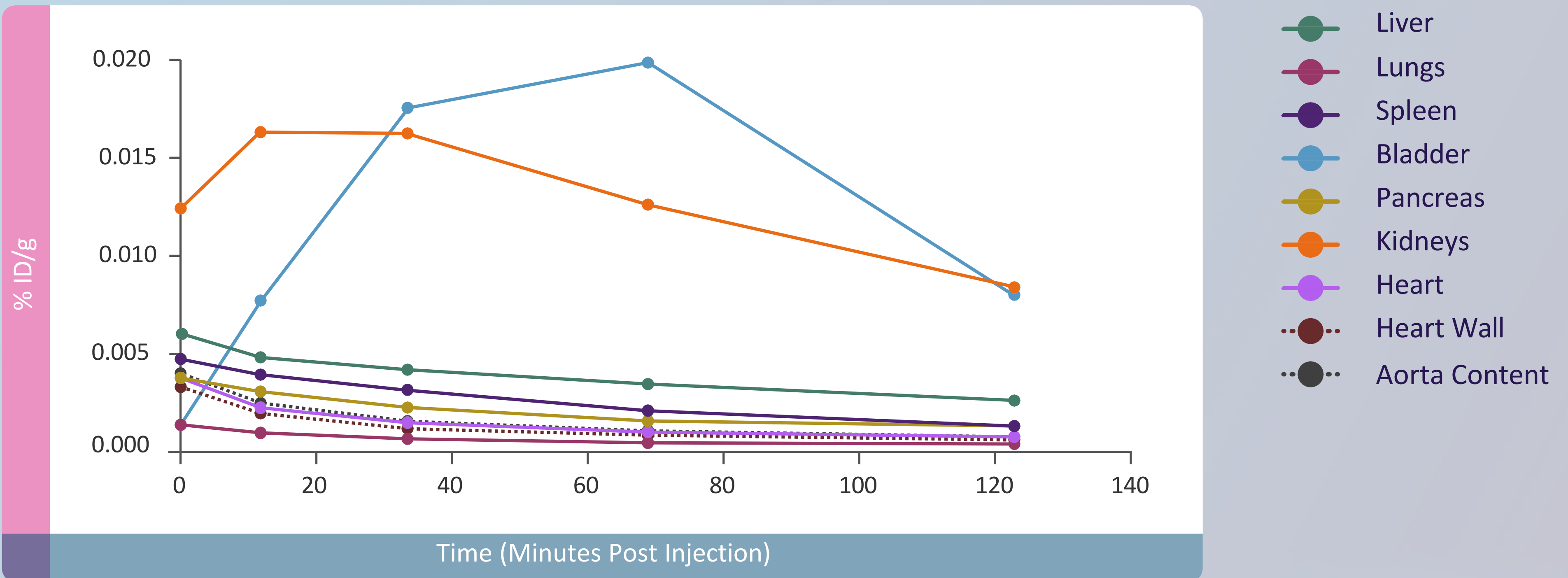
Piflufolastat (^{18}F): Physiological distribution in the pelvic area



- Urinary elimination: activity in the ureters (arrow) and urinary bladder (arrowhead)
- Activity in the ureters must be distinguished from eventual metastatic pelvic lymph nodes

Piflufolastat (^{18}F): Dosimetry

The effective dose resulting from the administration of a maximal recommended activity of 360 MBq for an adult weighing 70 kg is about 4.2 mSv.



4.6

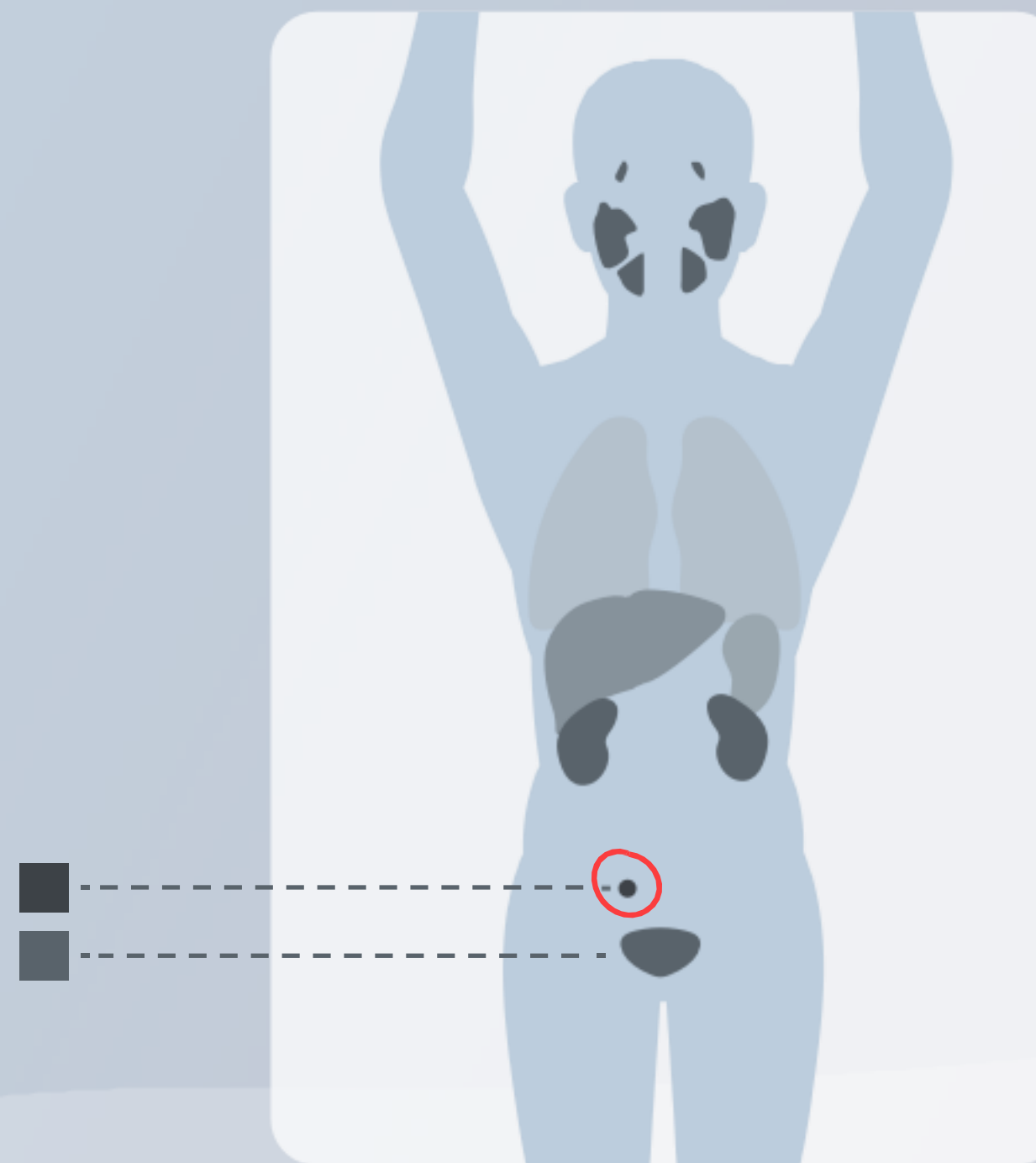
Piflufolastat (^{18}F) PET/CT: Interpretation

Piflufolastat (^{18}F) PET/CT: Interpretation

Piflufolastat (^{18}F) PET/CT should be interpreted by visual assessment.

Lesions should be considered suspicious if uptake is greater than physiologic uptake in that tissue or greater than adjacent background if no physiologic uptake is expected.

The examples of interpretation of piflufolastat (^{18}F) PET/CT are provided in Chapter 5, Case reports.

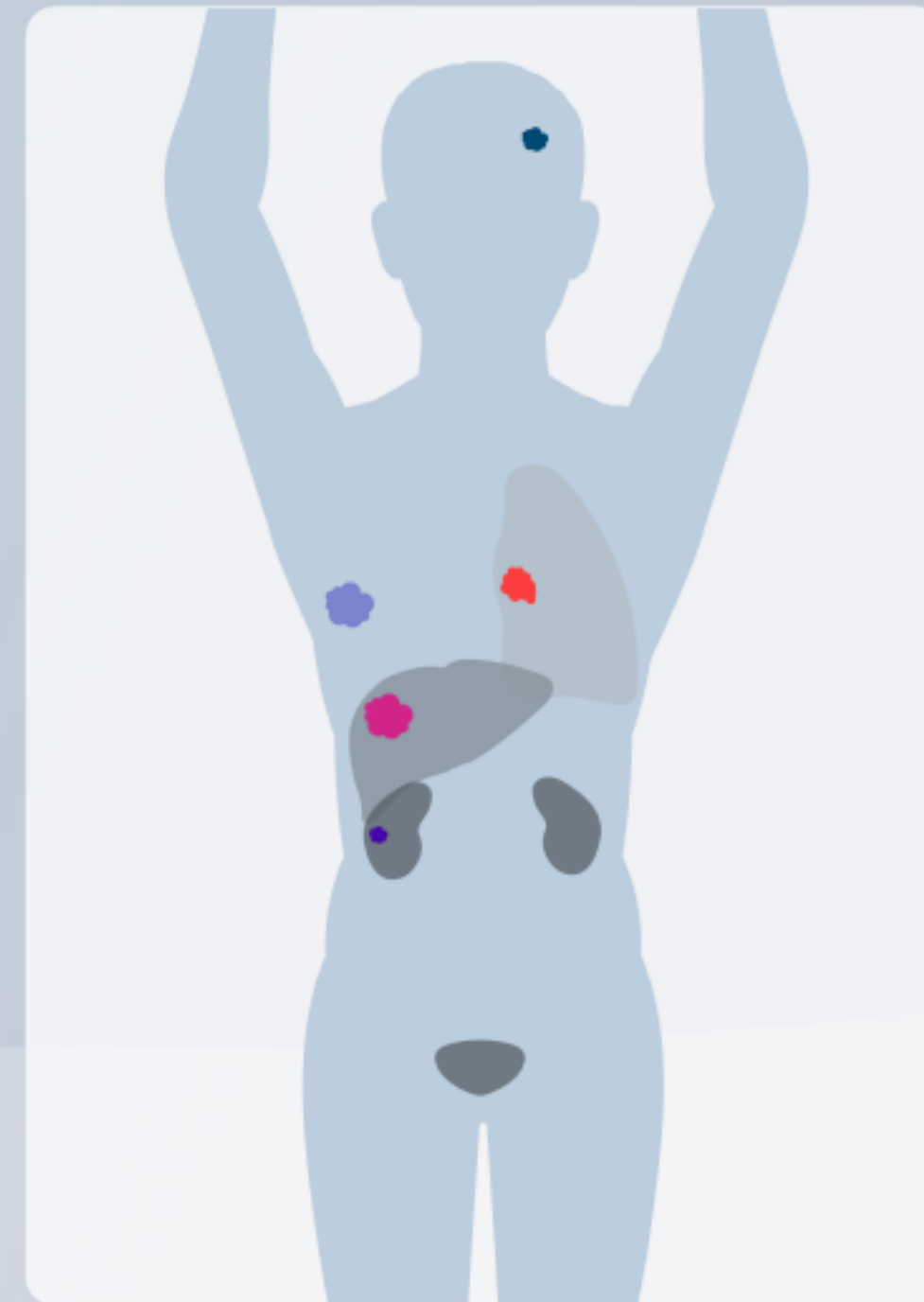

Piflufolastat (¹⁸F) PET/CT: Interpretation

PSMA can be expressed in prostate cancer, but can also be observed in other neoplasms (renal cell carcinoma, hepatocarcinoma, breast cancer, lung cancer and other malignancies).

Or

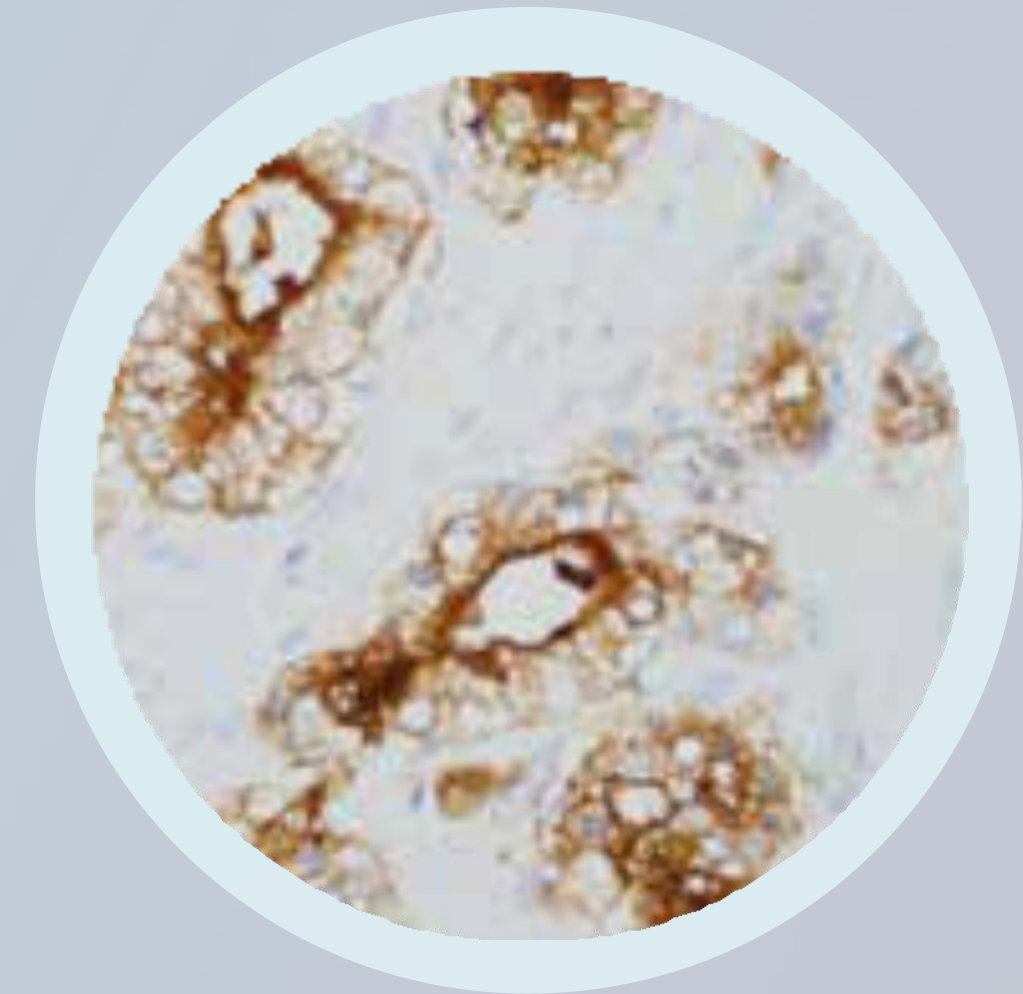
Benign conditions (e.g. hemangioma, ganglia, Paget's disease, sarcoidosis, granulomatosis, etc.), potentially leading to false positive findings.



Piflufolastat (¹⁸F) PET/CT: Interpretation

The diagnostic performance of piflufolastat (¹⁸F) PET/CT for metastatic pelvic lymph nodes prior to initial definitive therapy may be affected by metastatic risk factors of the disease such as Gleason score or initial serum PSA level.

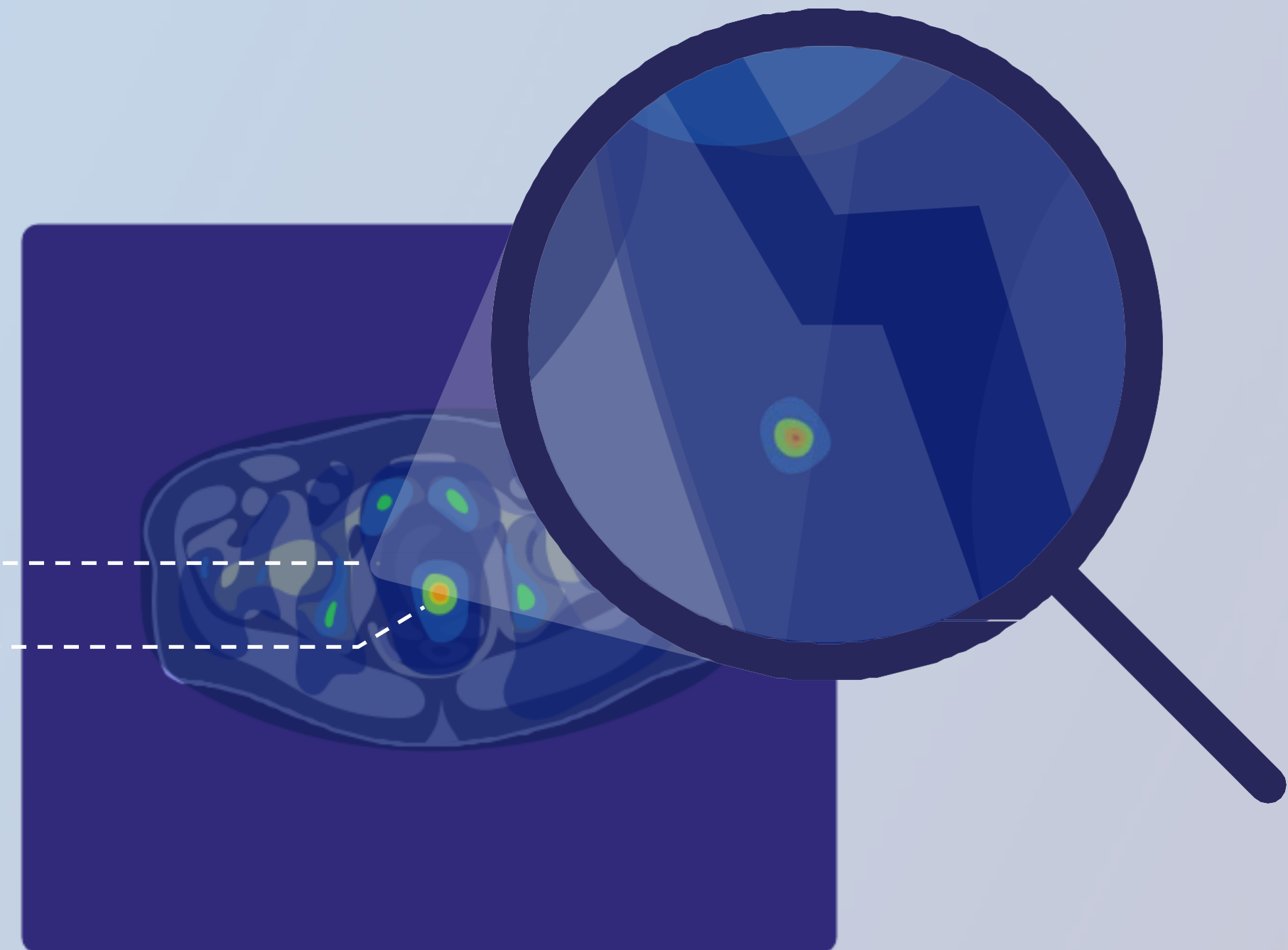
The diagnostic performance of piflufolastat (¹⁸F) PET/CT for imaging of patients with BCR may be affected by the tumour mass of prostate cancer and serum PSA levels.



Piflufolastat (^{18}F) PET/CT: Interpretation

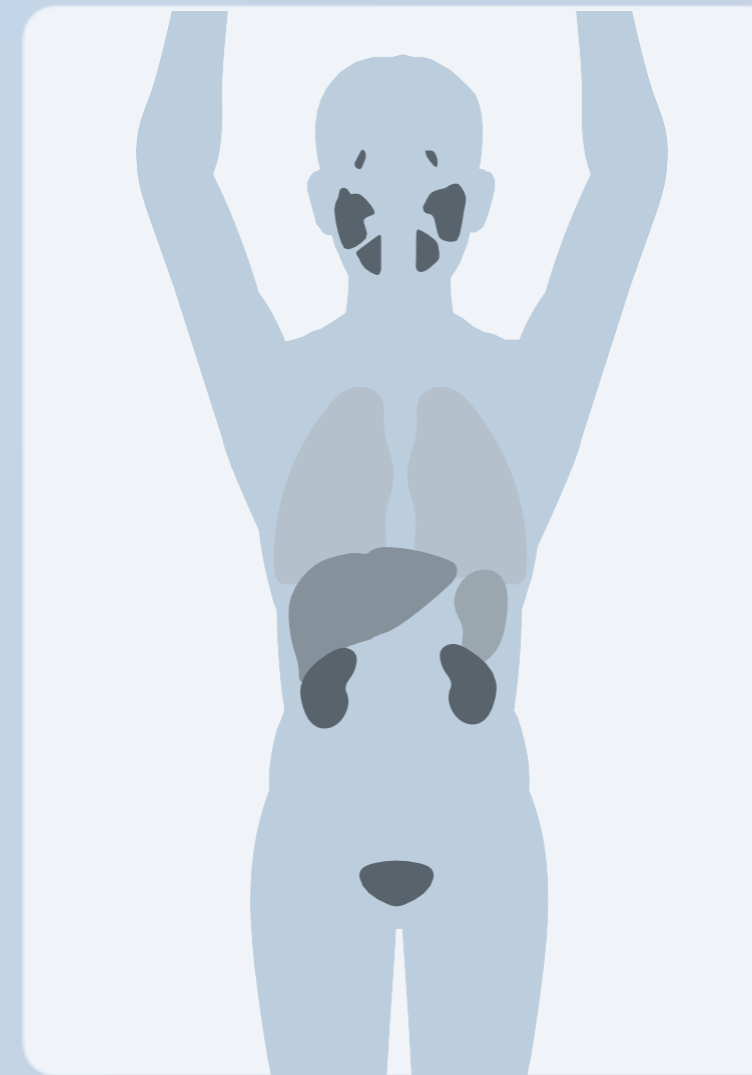Any lesion under spatial resolution of PET may be missed by piflufolastat (^{18}F) PET/CT.

Lesions

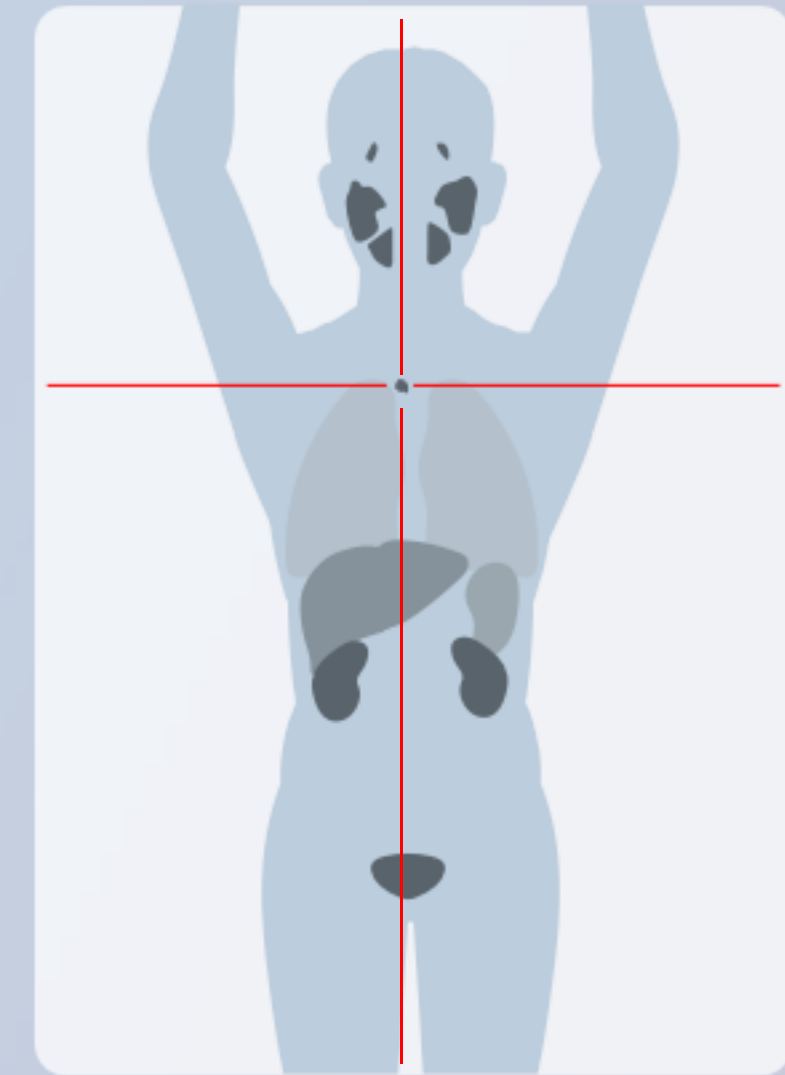


Piflufolastat (^{18}F) PET/CT: Interpretation

A negative piflufolastat (^{18}F) PET/CT does not rule out the presence of prostate cancer and a positive PET/CT does not confirm the presence of prostate cancer.



Positive



Negative

CHAPTER 5

Case reports

5.1

Initial staging, biochemical recurrence, false positive findings, false negative findings, incidental findings

Case report on initial staging #1

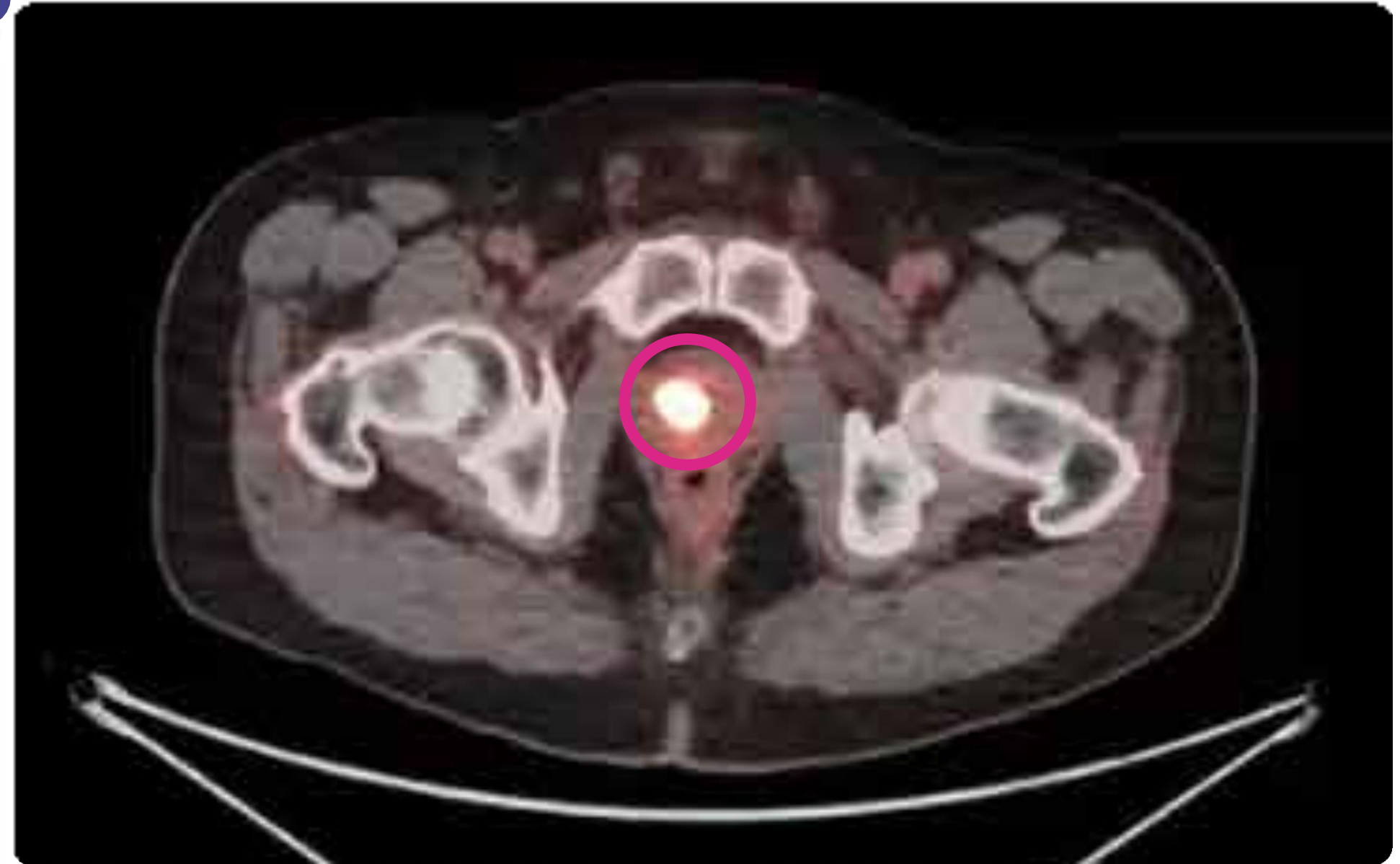
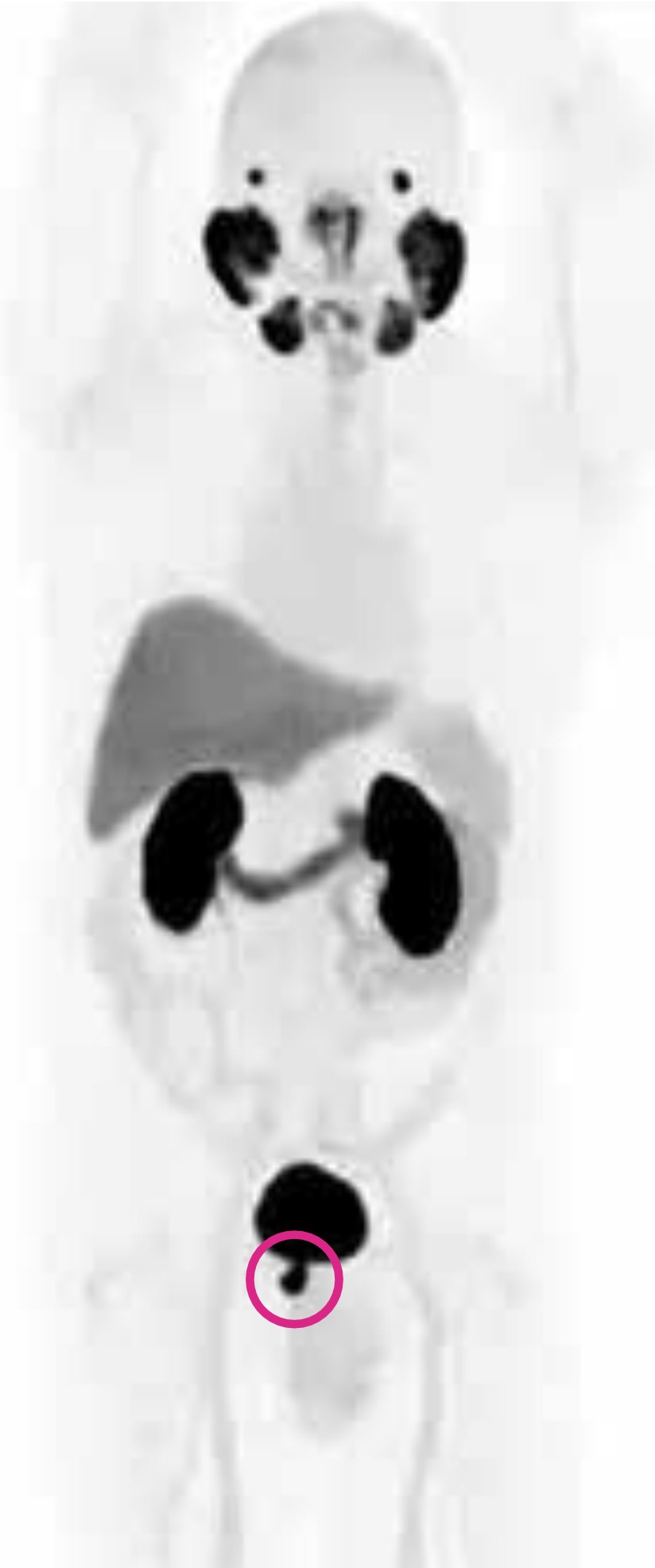Patient's history

63-year-old man.

Gleason score 9 (4+5).

PSA 19.3 ng/mL.

Case report on initial staging #1



Piflufolastat (^{18}F) PET/CT findings

Increased uptake in the prostate.
No evidence of local or distant metastasis.

Case report on initial staging #2

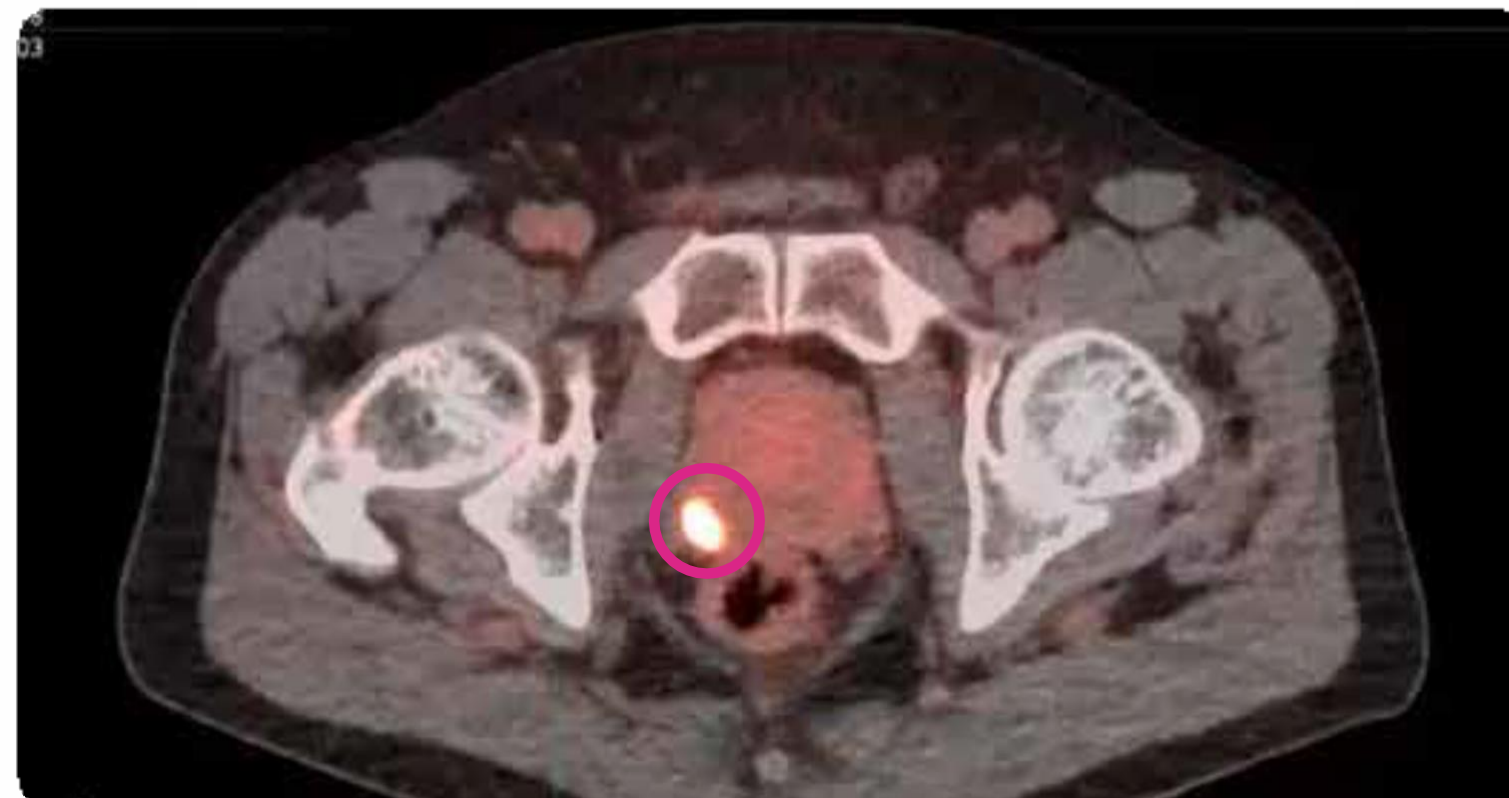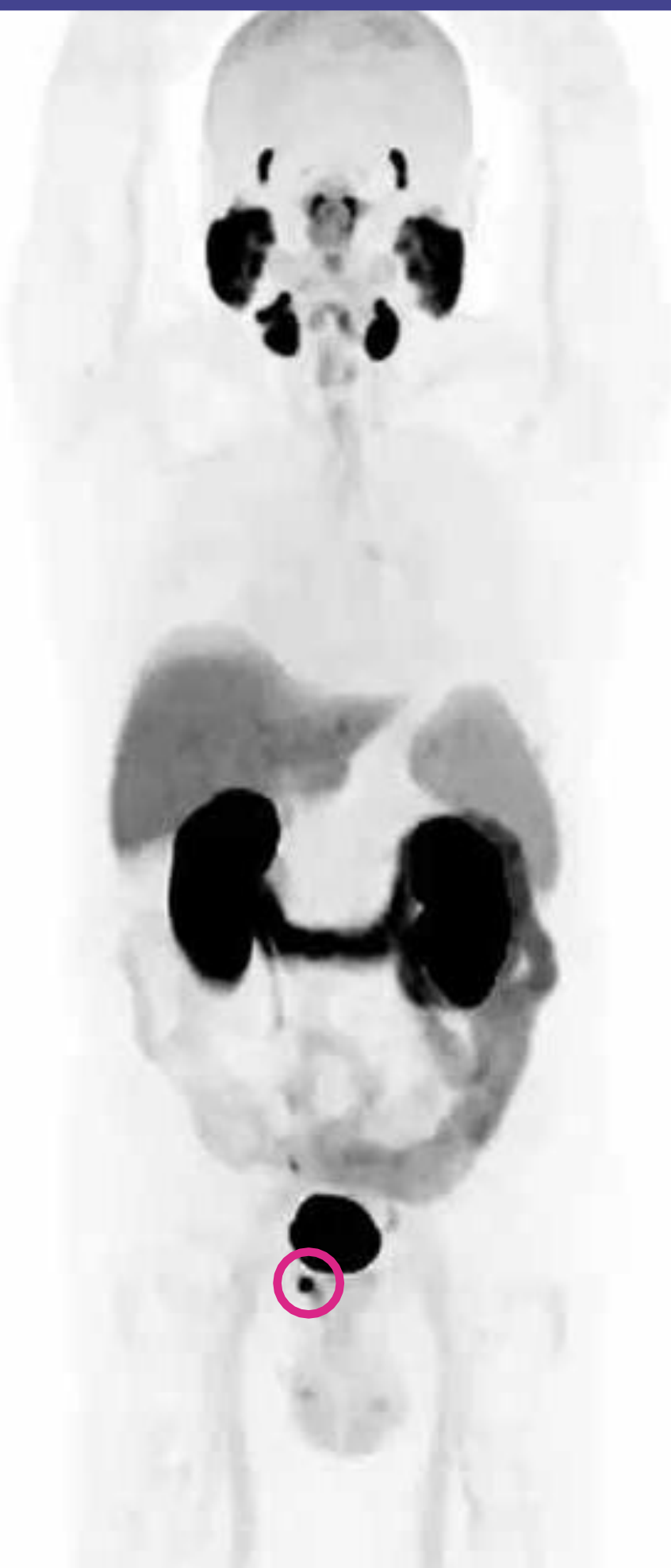Patient's history

70-year-old man.

Gleason score 8 (4+4).

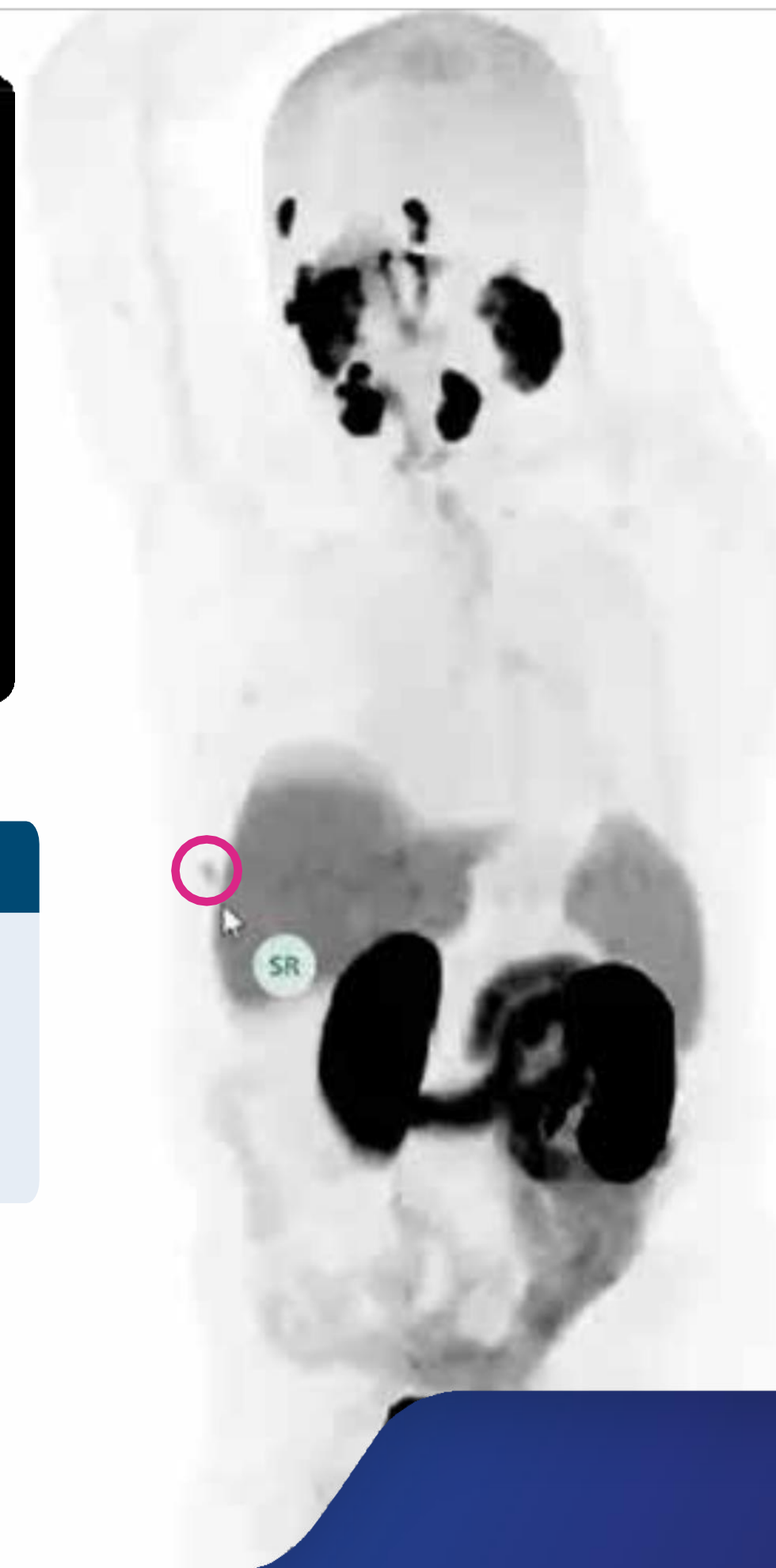PSA 5.28 ng/mL.

Case report on initial staging #2



Piflufolastat (^{18}F) PET/CT findings

Increased uptake in the prostate.
Nonspecific uptake in the right rib.



Case report on BCR #1

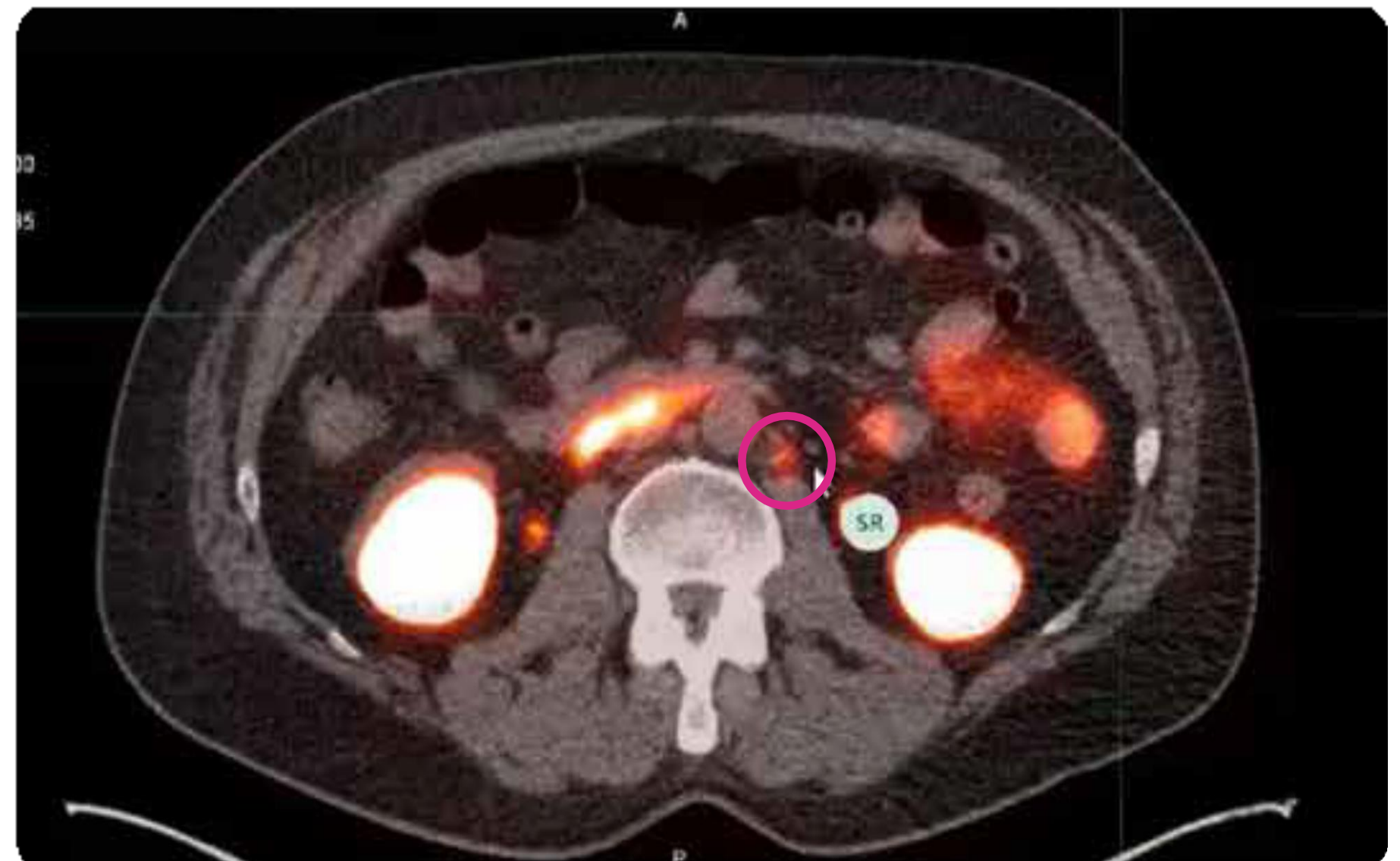
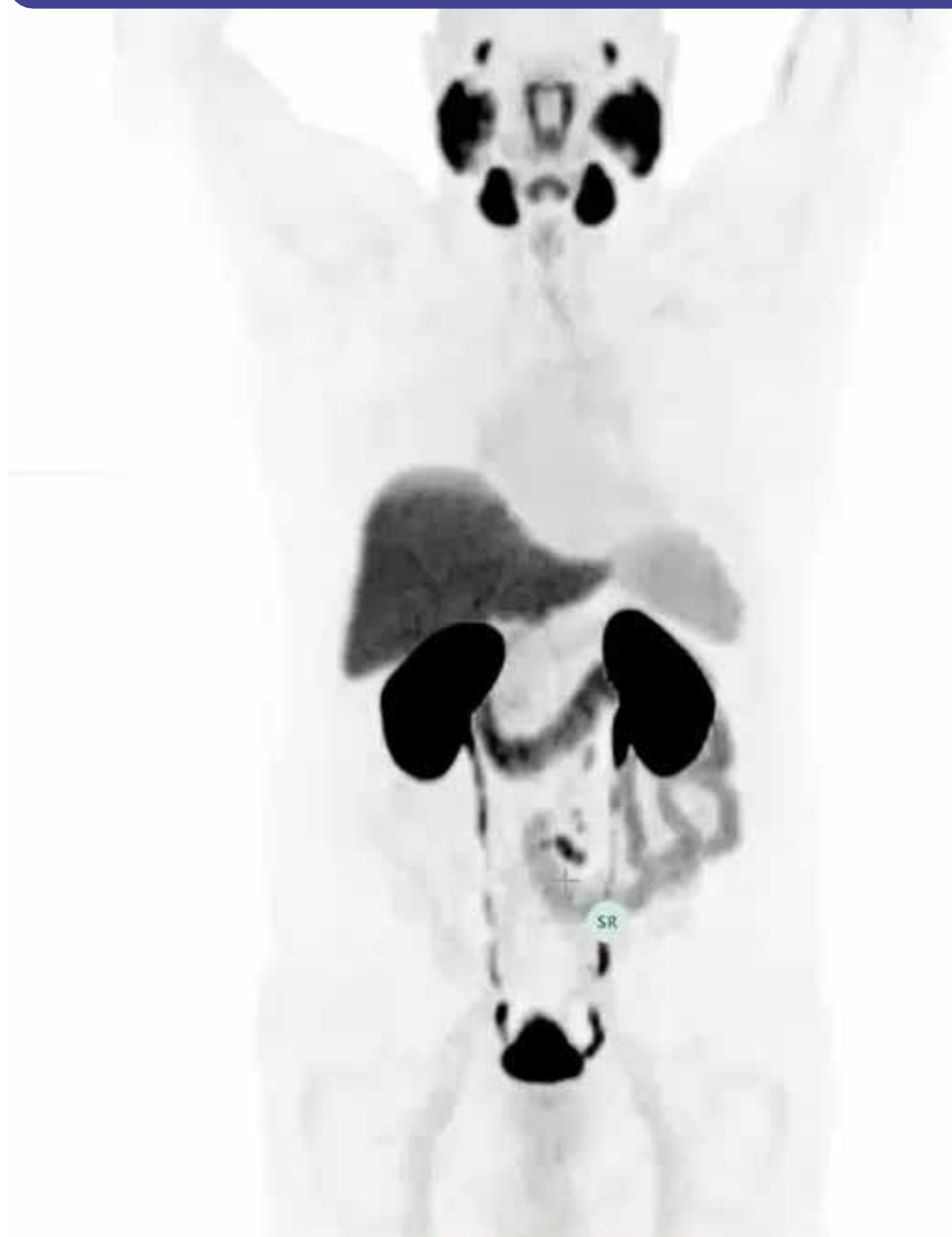
Patient's history

72-year-old man.

After radiotherapy.

PSA 7.24 ng/mL.

Case report on BCR #1



Piflufolastat (^{18}F) PET/CT findings

Increased uptake in the retroperitoneal lymph node.

Case report on BCR #2

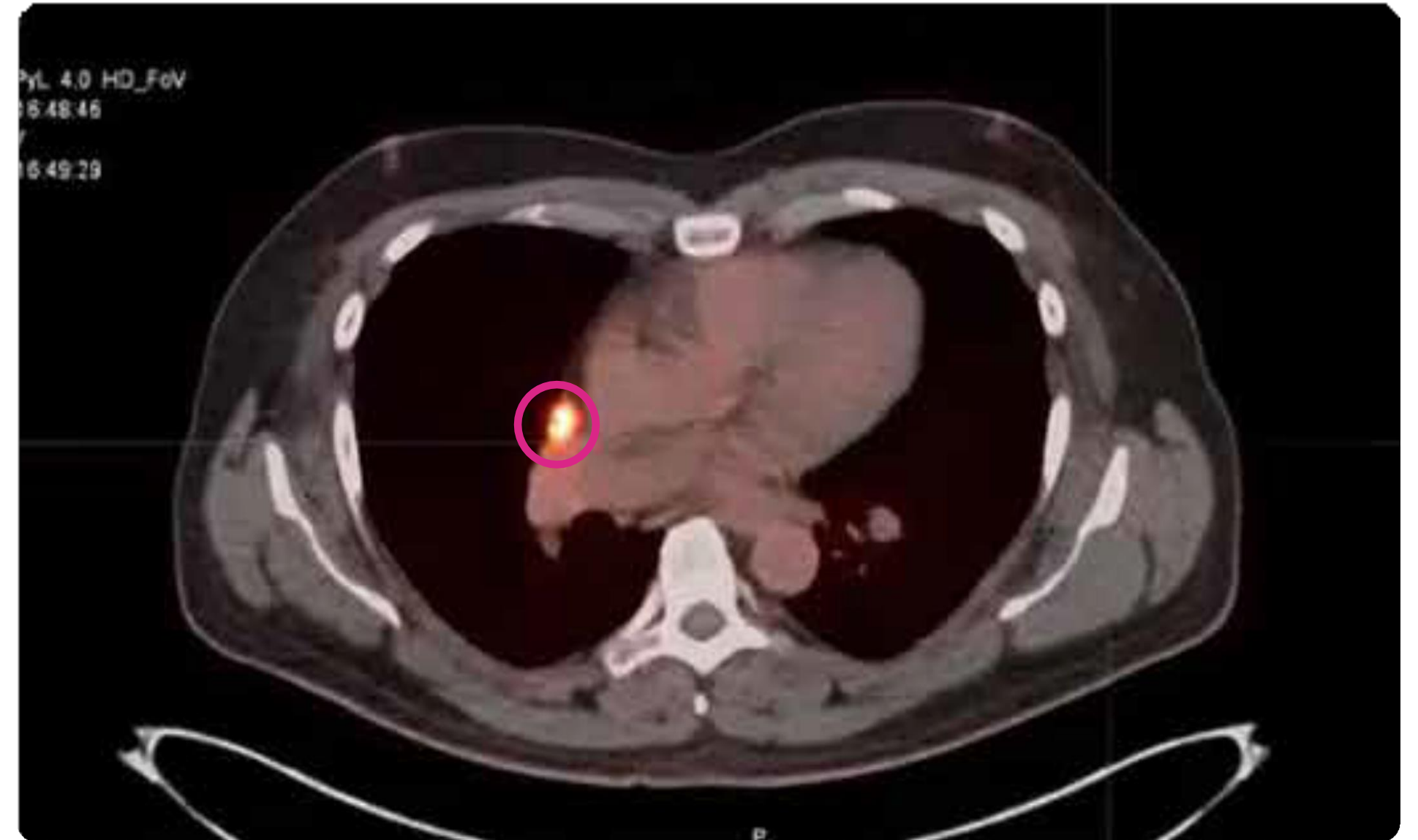
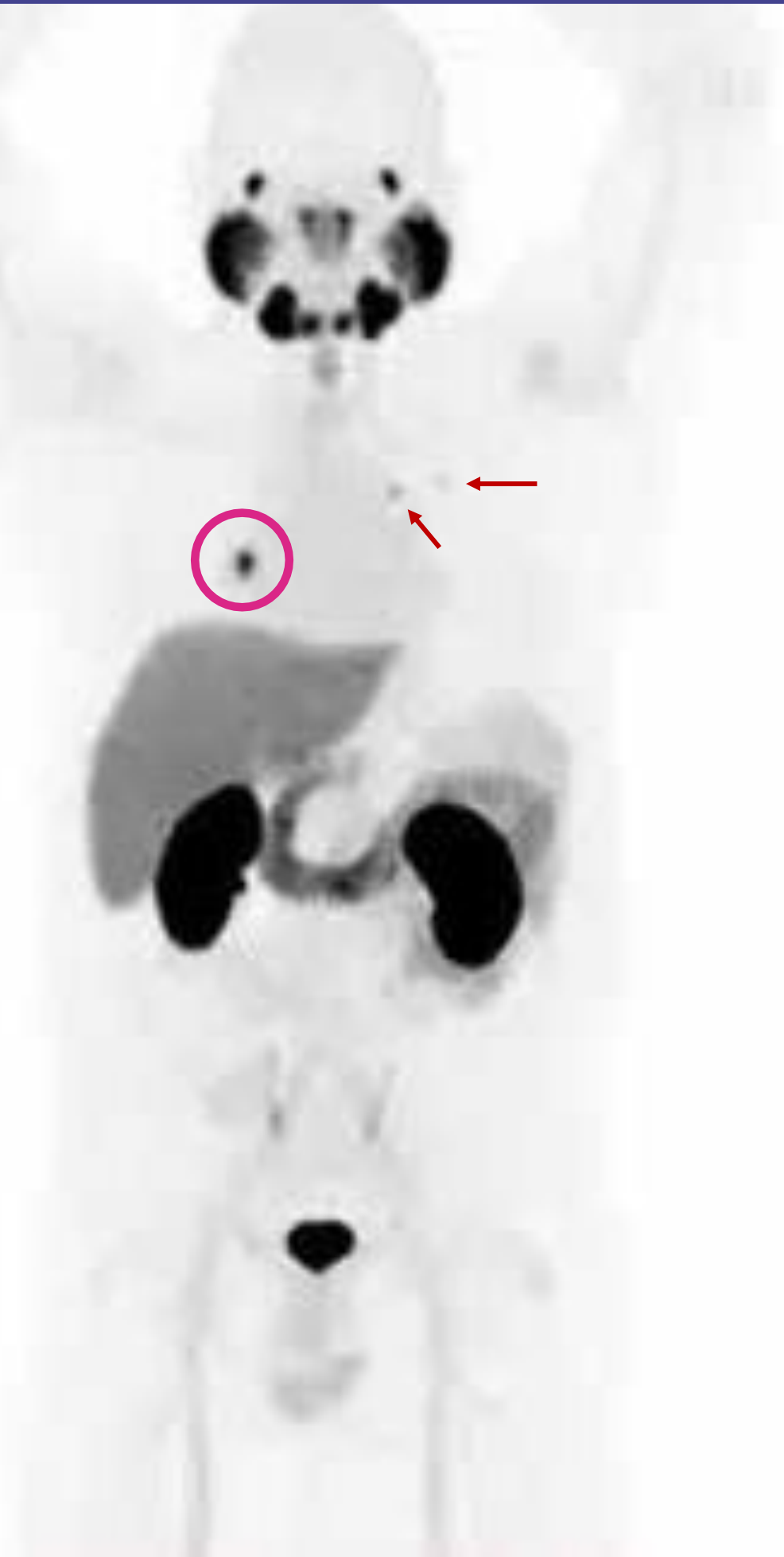Patient's history

58-year-old man.

History of radical prostatectomy + eLND and radiotherapy.

PSA 2.74 ng/mL.

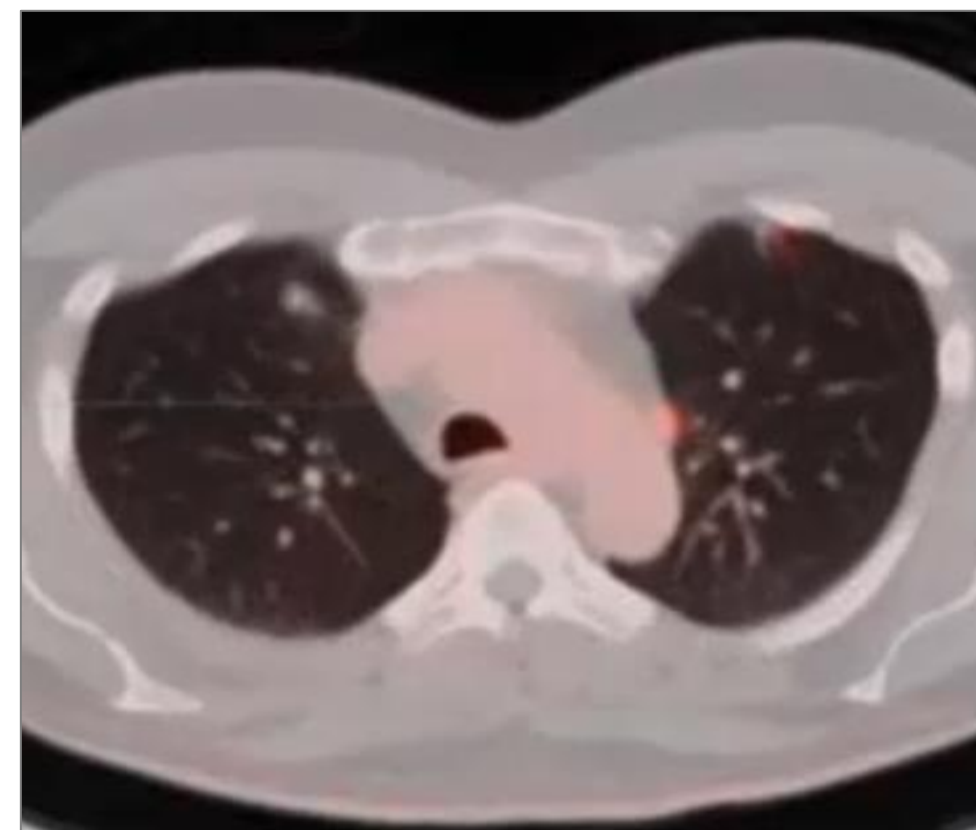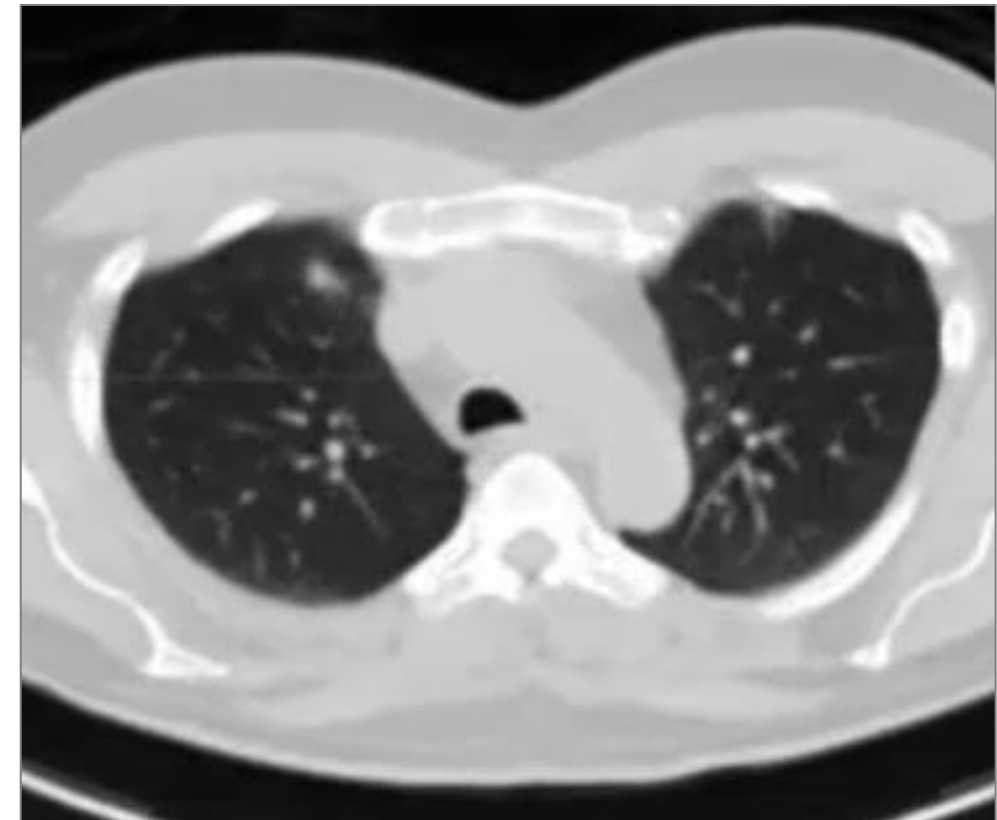
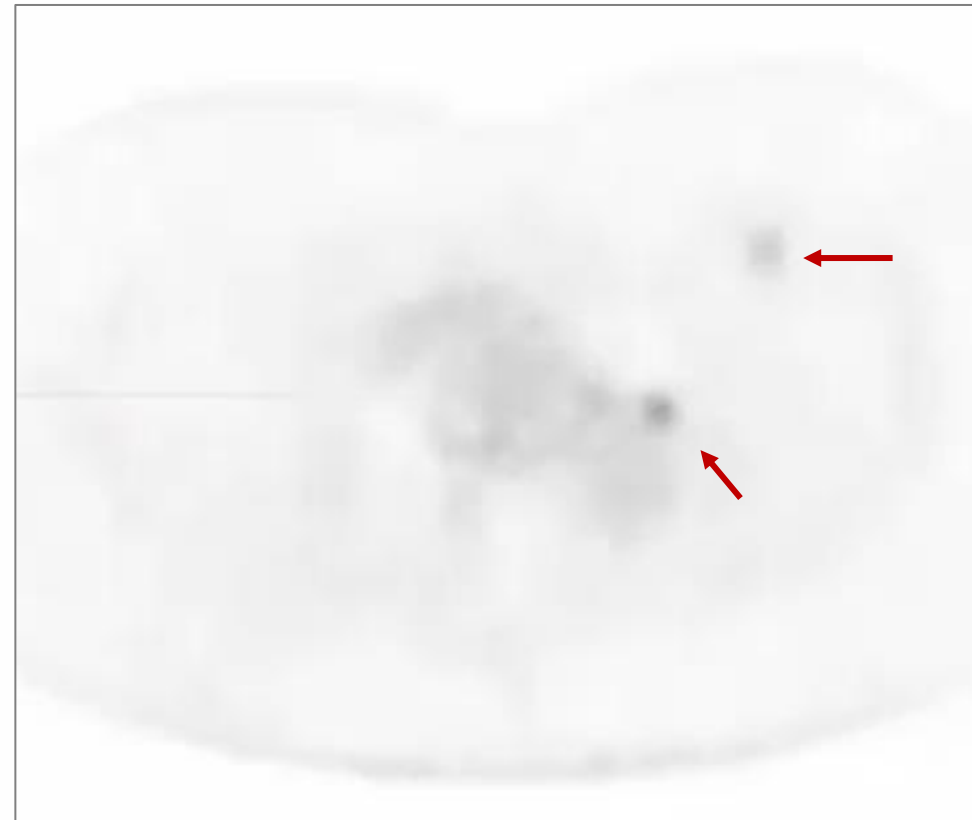
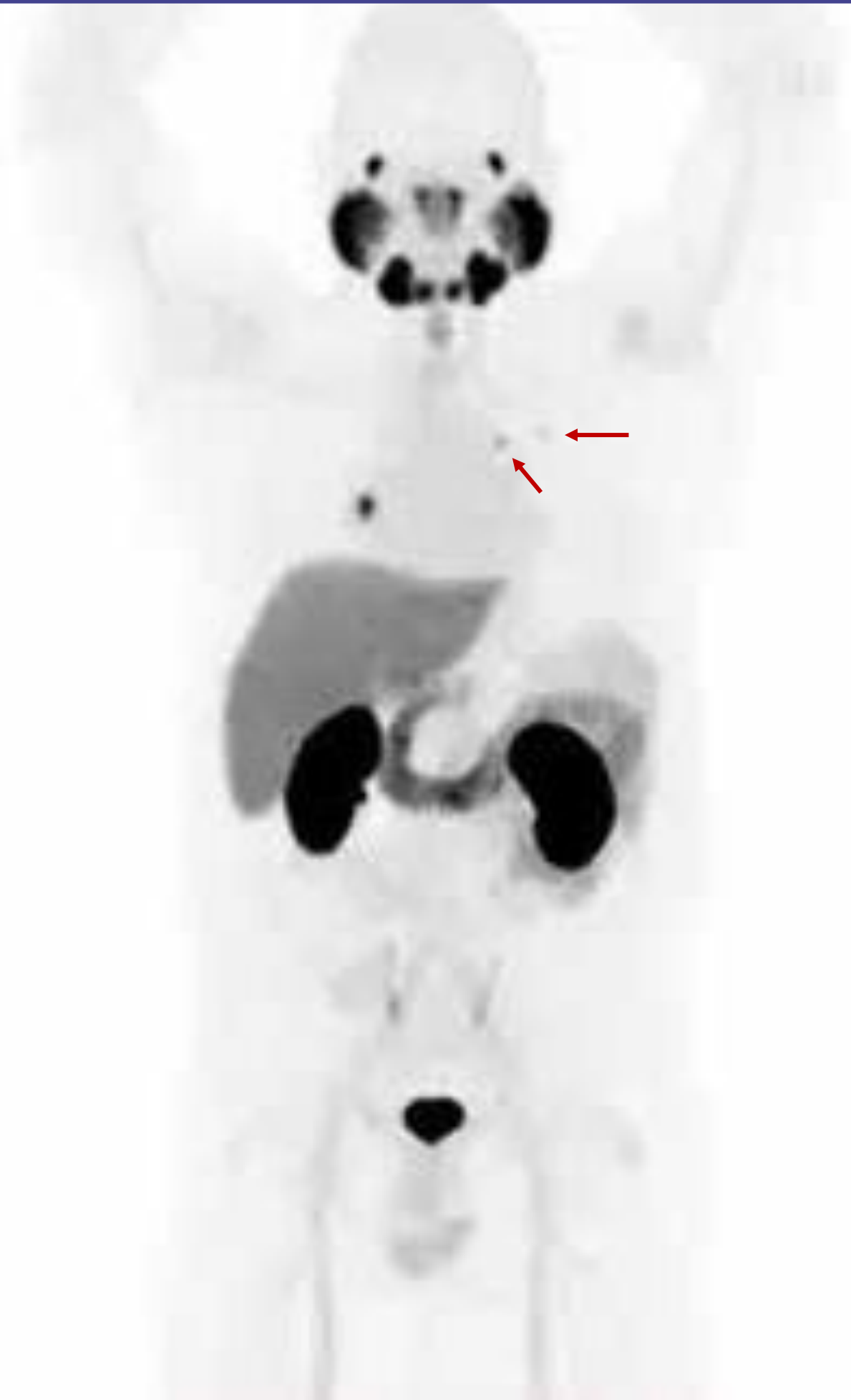Case report on BCR #2



Piflufolastat (^{18}F) PET/CT findings

Increased uptake in the right hilar lymph node, confirmed as metastasis of prostate cancer and increased uptake in two small infiltrates in the left lung confirmed as metastases of prostate cancer by follow-up.

Case report on BCR #2



Case report on false positive findings #1

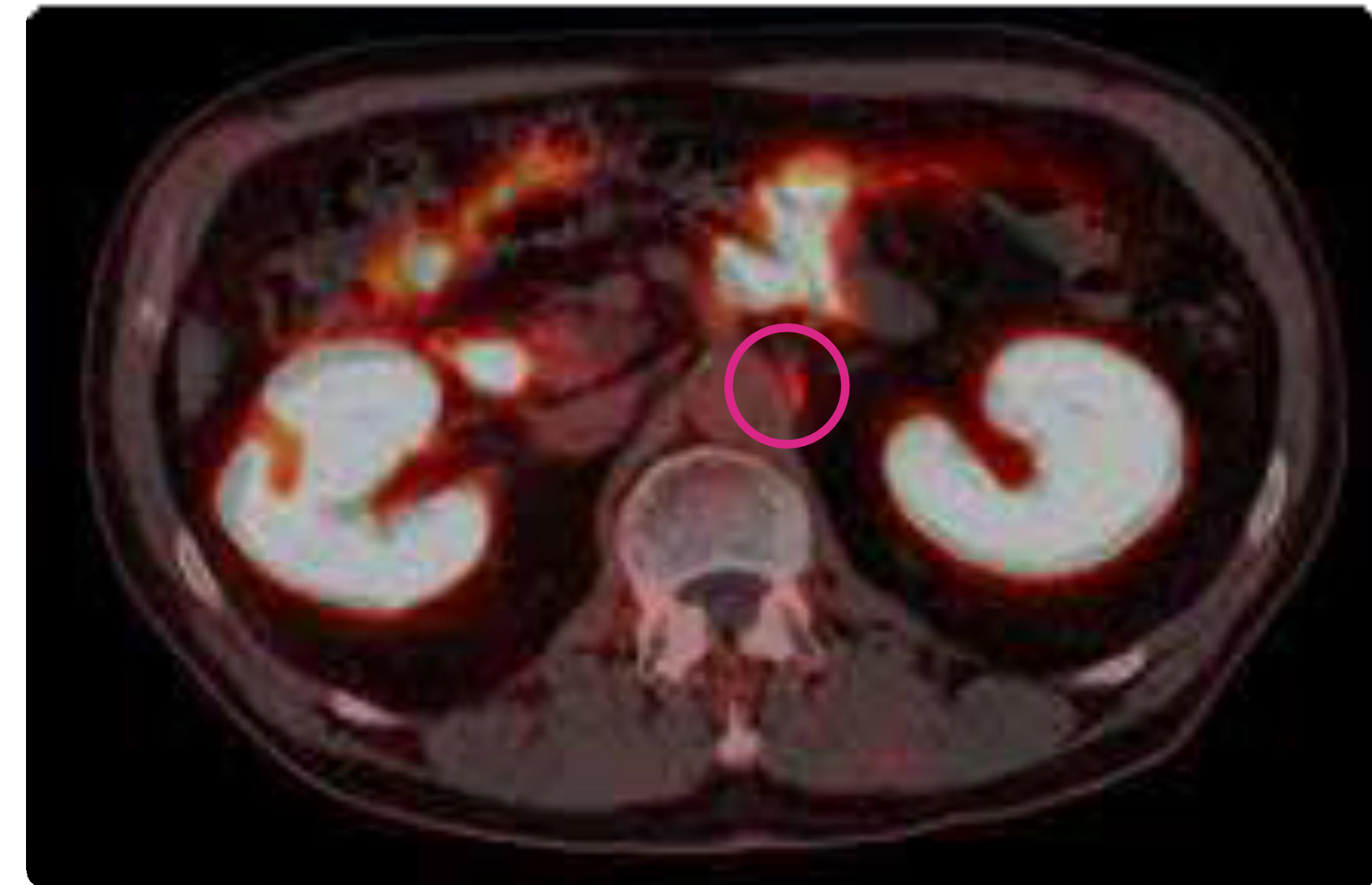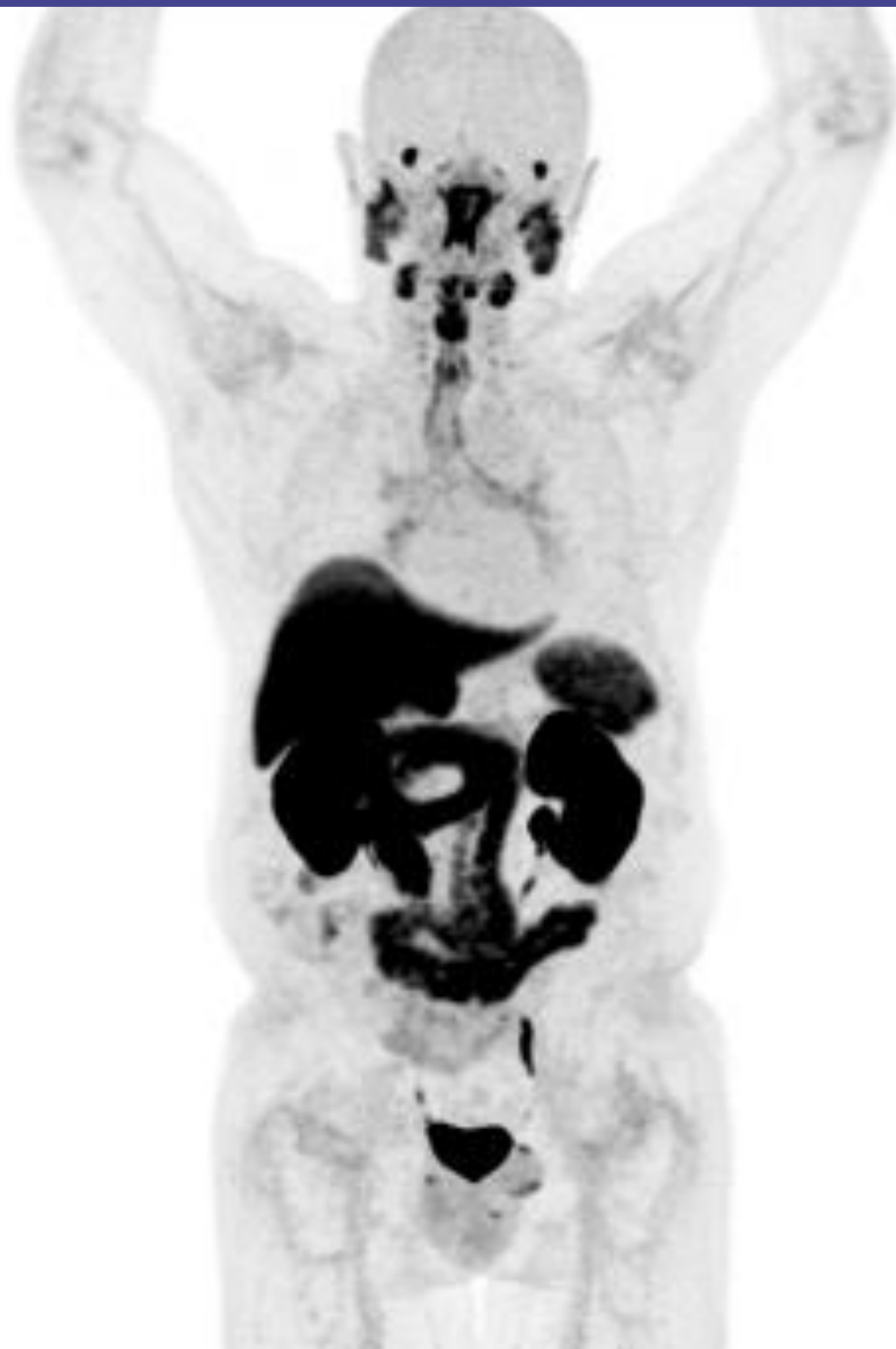Patient's history

73-year-old man.

History of radical prostatectomy without eLND.

PSA 0.22 ng/mL.

Case report on false positive findings #1



Piflufolastat (^{18}F) PET/CT findings

Increased uptake in the left coeliac ganglia mimicking a paraaortic lymph node.

Case report on false positive findings #2

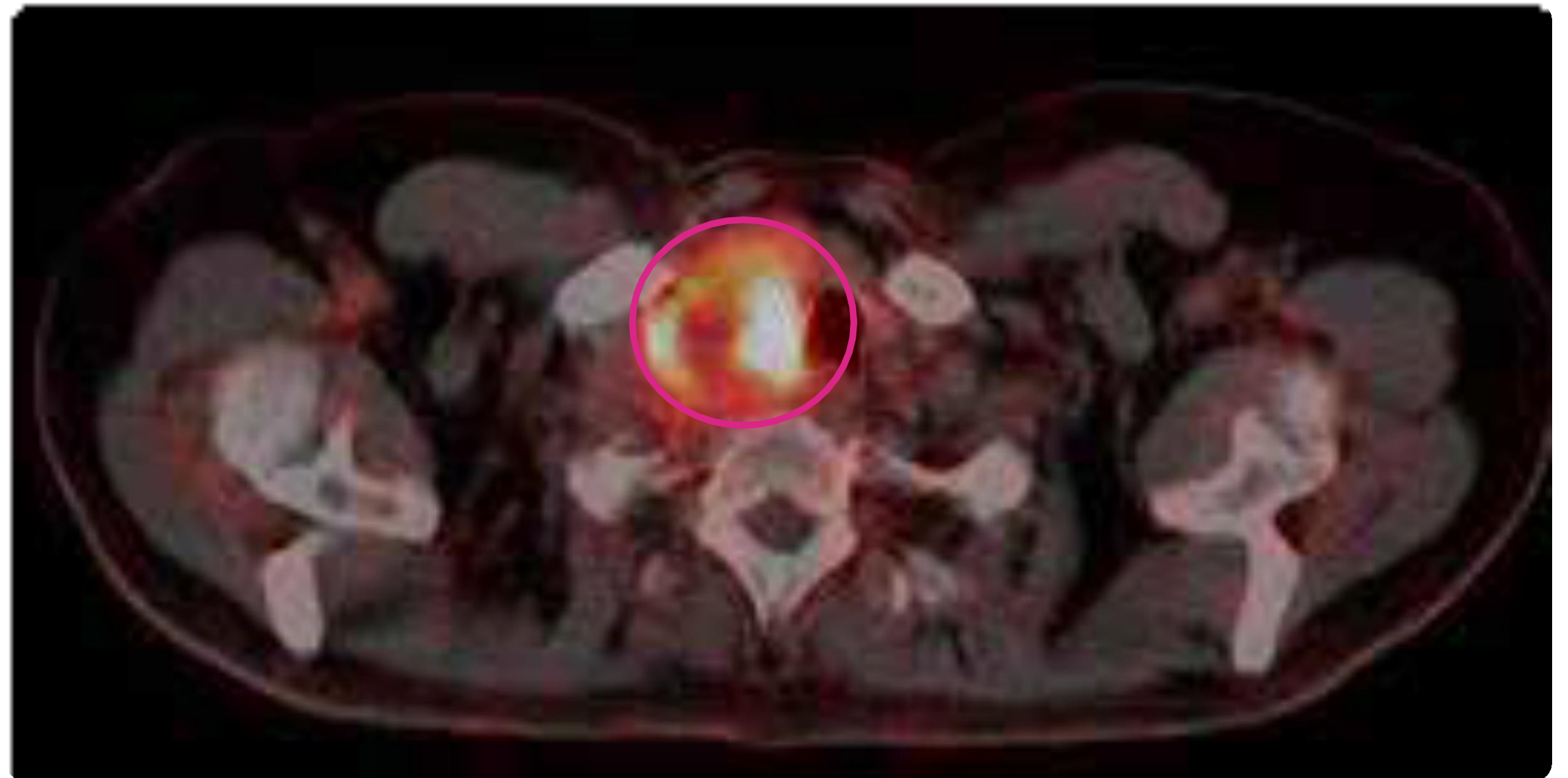
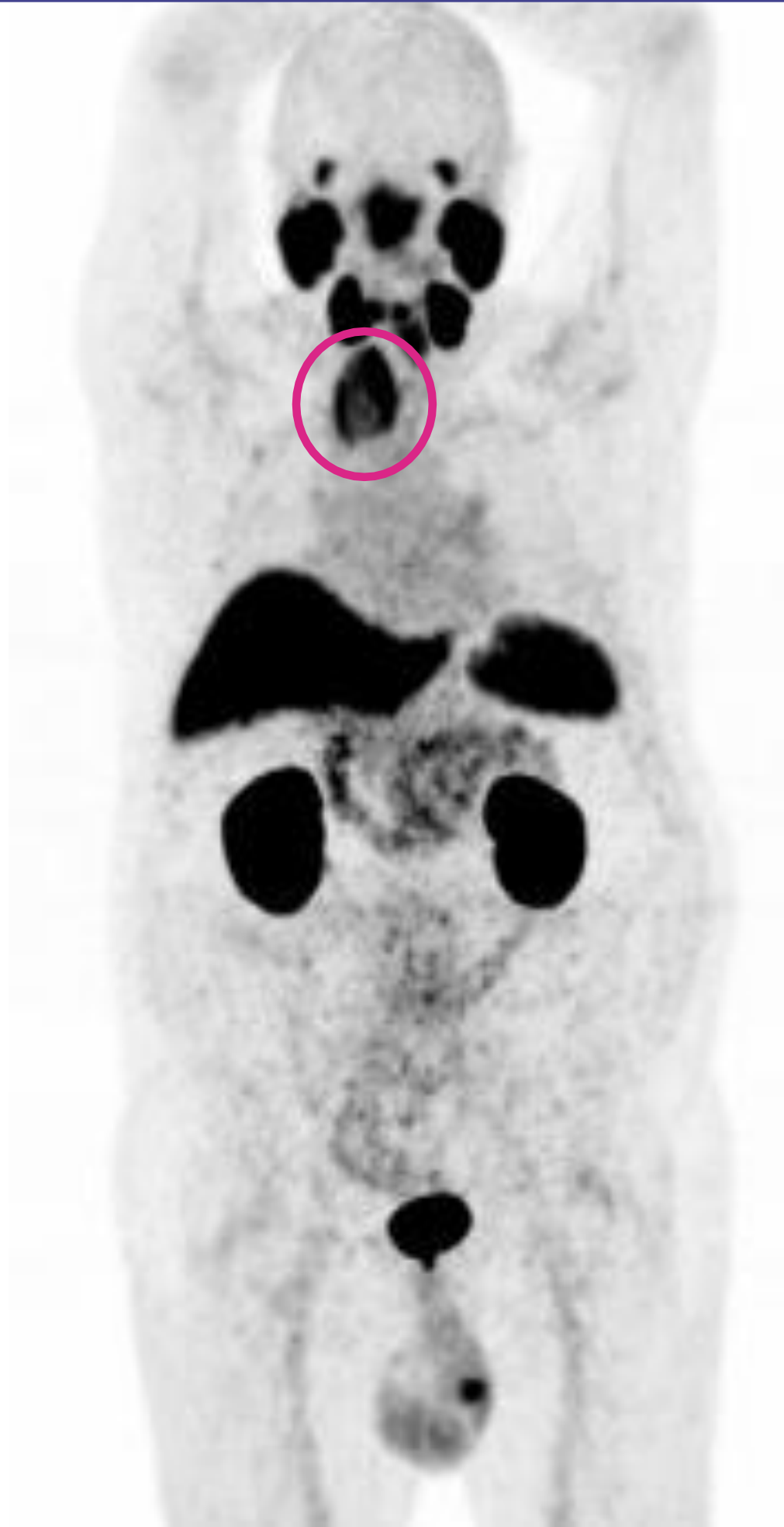Patient's history

73-year-old man.

History of radical prostatectomy without eLND.

PSA 0.62 ng/mL.

Case report on false positive findings #2



Piflufolastat (^{18}F) PET/CT findings

Intense uptake in the voluminous nodule in the right lobe of the thyroid gland.

Case report on false negative findings #1

Patient's history

67-year old man.

History of radical prostatectomy with eLND

PSA 0,71 ng/mL

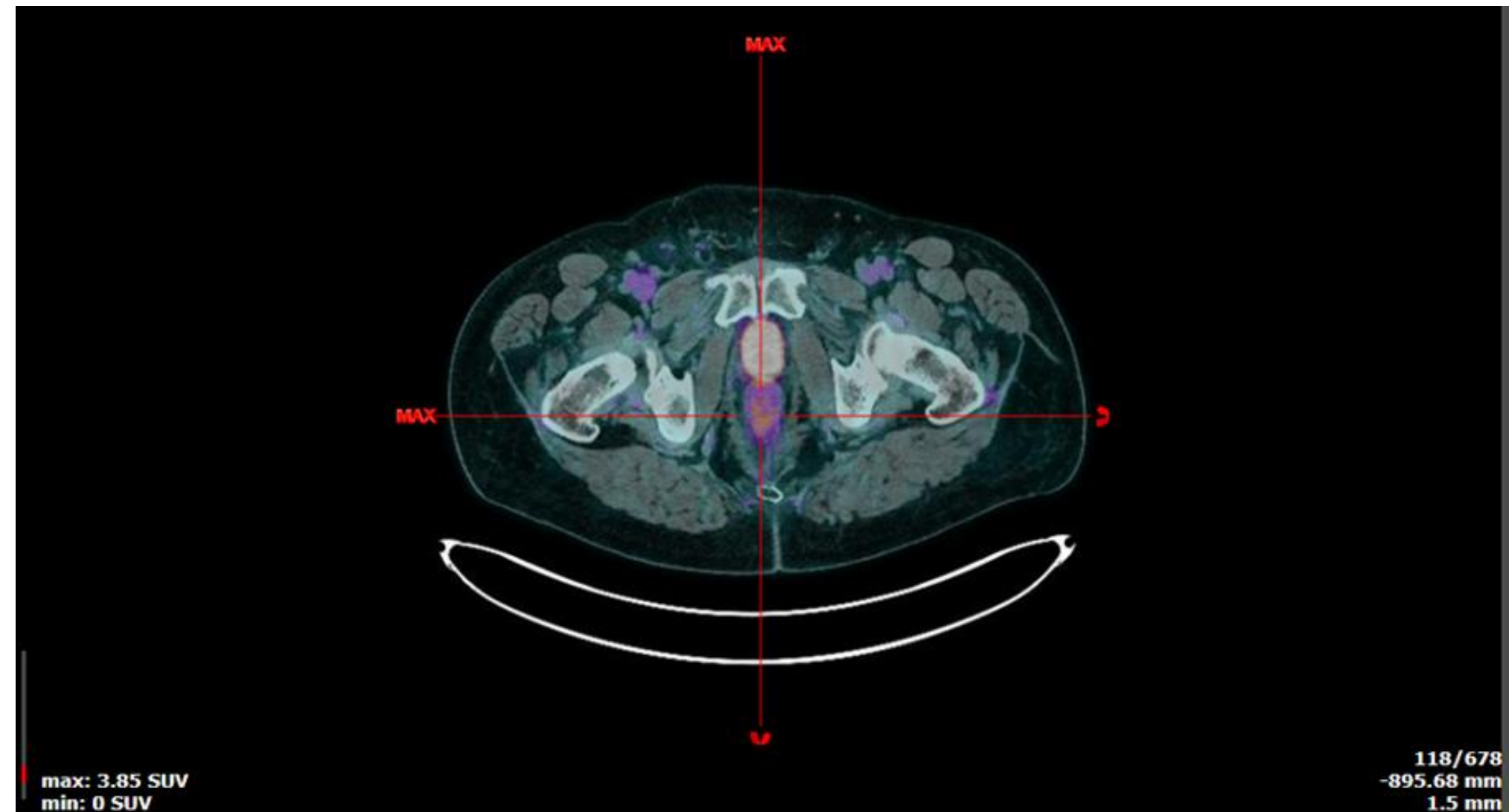
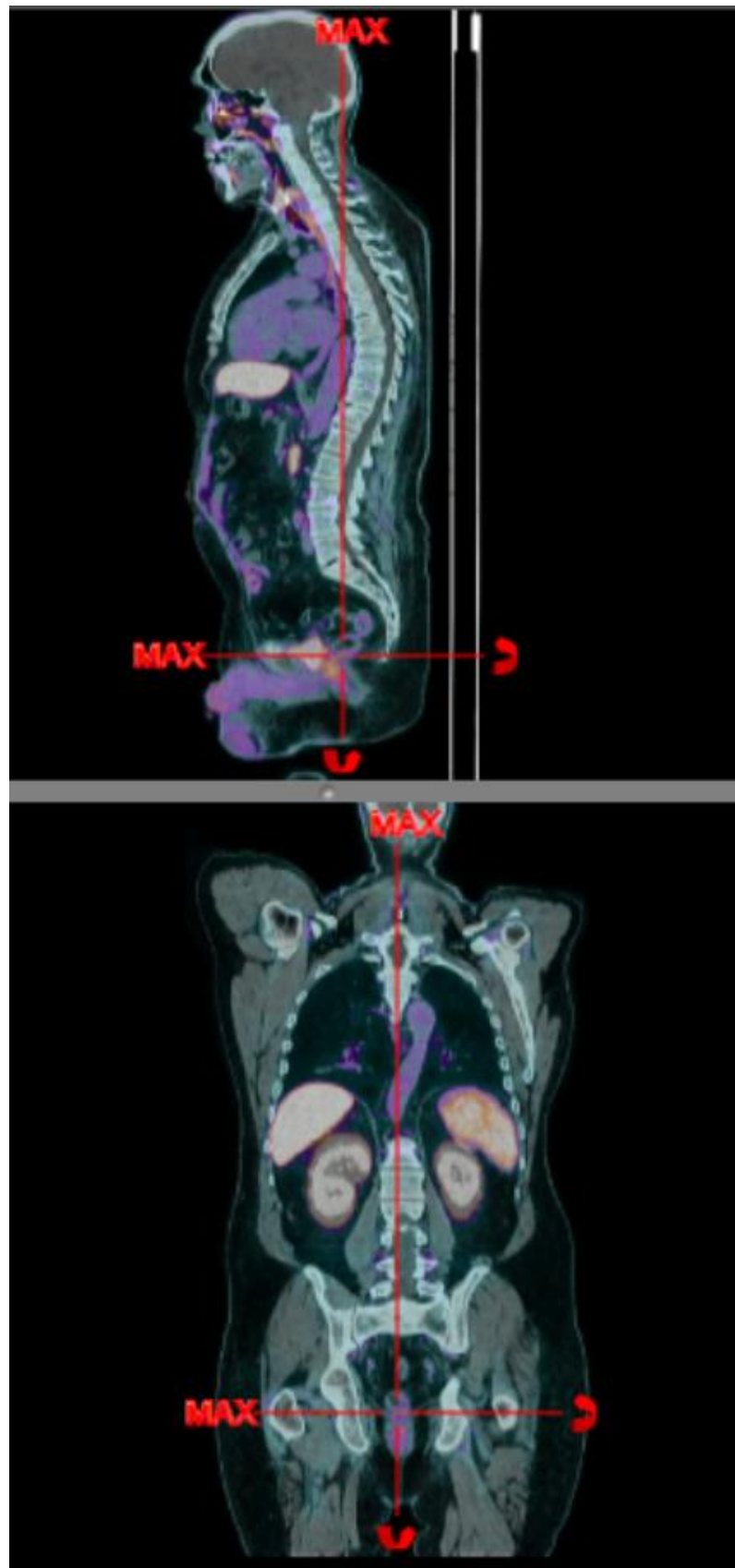
No clinical symptoms

Management after PET/CT

Salvage RT of the prostate bed

PSA drop to 0.07 ng/mL at last follow-up (5 months after RT initiation)

Case report on false negative findings #1



Piflufolastat (^{18}F) PET/CT findings

No pathological uptake in the prostate bed
The finding was retrospectively interpreted as false negative since the serum PSA levels decreased after radiation therapy of the prostate bed suggesting the presence of the microscopic disease in the area, non-detectable by PET/CT

Case report on false negative findings #2

Patient's history

76-year old man.
Proven high-risk prostate cancer
PSA 110 ng/mL

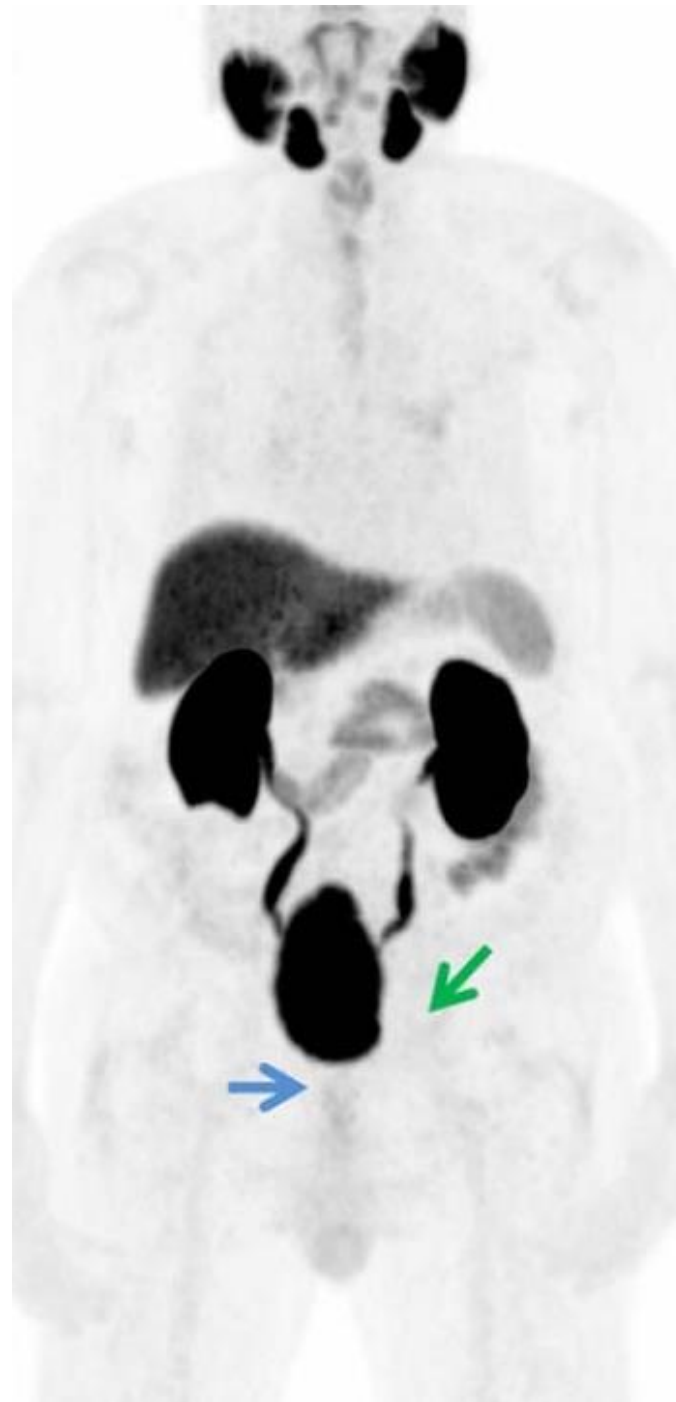Piflufolastat (¹⁸F) PET/CT findings

No pathological uptake

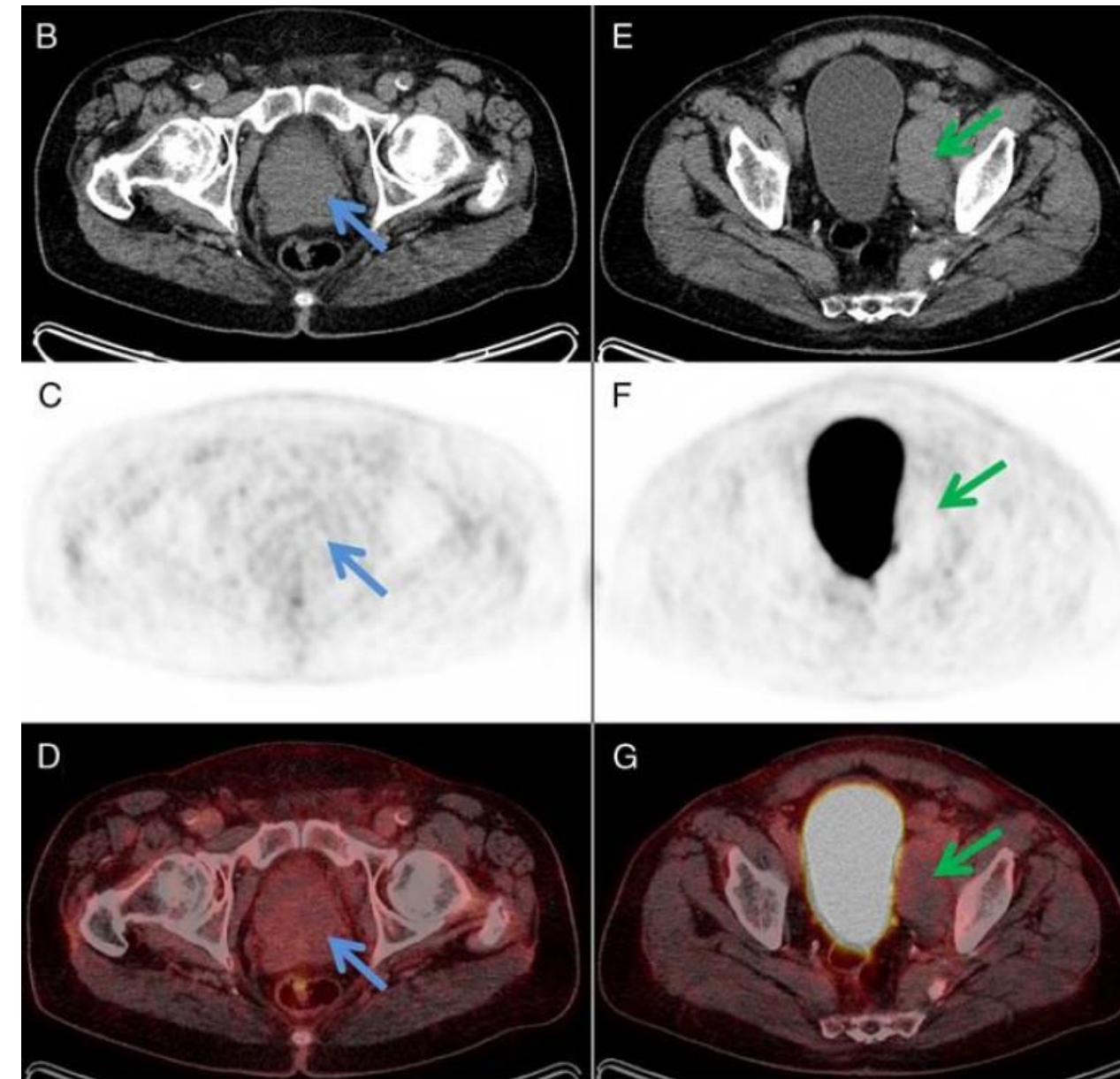
Management after PET/CT

Histopathology of LN revealed metastasis from an adenocarcinoma of the prostate without neuroendocrine differentiation.
The patient was treated with total androgen blockage and docetaxel. In 2 months, PSA decreased to 8.0 ng/mL.

Case report on false negative findings #2



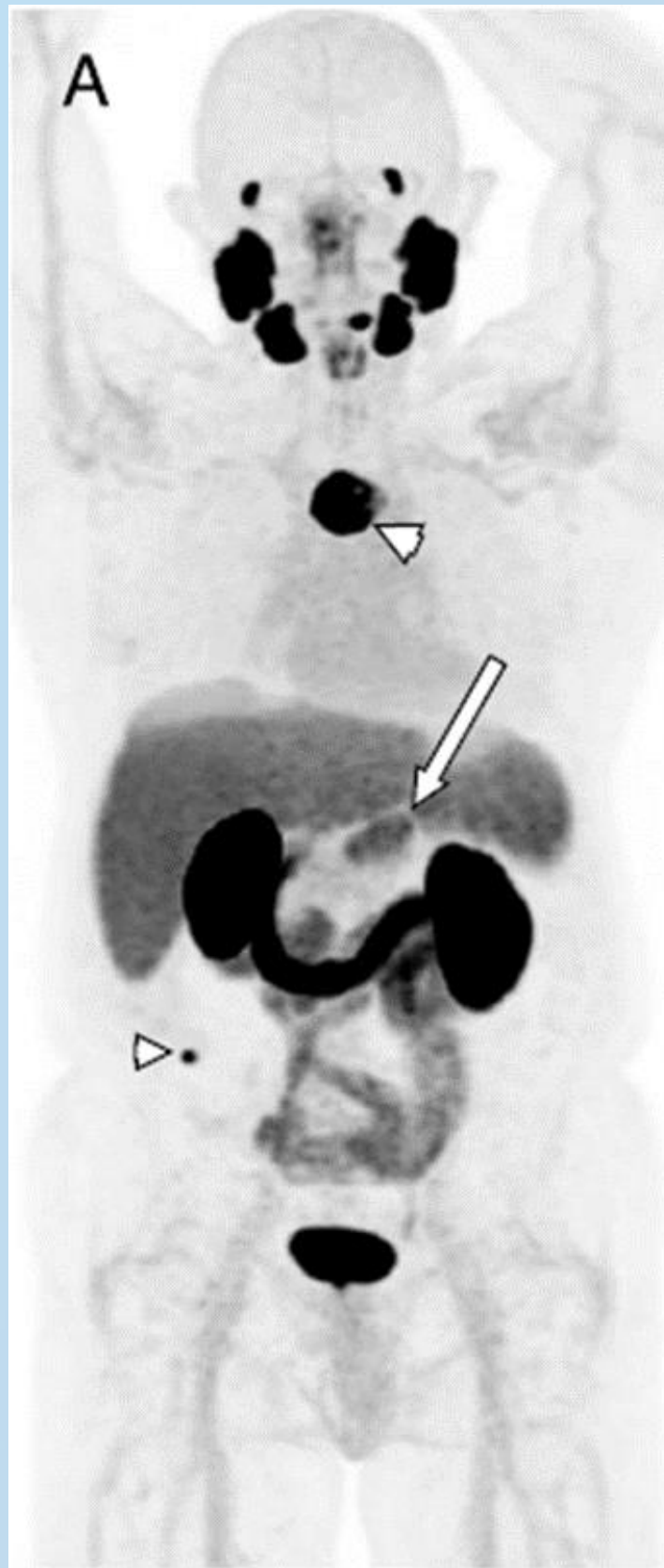
PET - MIP



Patient with confirmed prostate cancer with no neuroendocrine differentiation, with Gleason score 3+4=7 and initial serum concentration of PSA 110 ng/mL. The lymph node metastases of prostate cancer were confirmed by biopsy.

In this rare case, no increased piflufolastat (^{18}F) uptake was visualized in the enlarged prostate (B–D, blue arrow). Low-dose CT for attenuation correction and anatomical mapping showed enlarged lymph nodes in the left parailiac region, of which the largest node had dimensions of 4.2 x 7.9 cm (E, green arrow). In those nodes, no increased piflufolastat (^{18}F) uptake was visualized (F, G, green arrow).

Case report on incidental findings #1



Patient's history

79-year old man.

Gleason 9 (5+4)

Patient treated with radiation and hormonal therapy

PSA nadir: 0,1 ng/ml

PSA 22 months after the treatment: 3,2 ng/mL

Piflufolastat (^{18}F) PET/CT findings

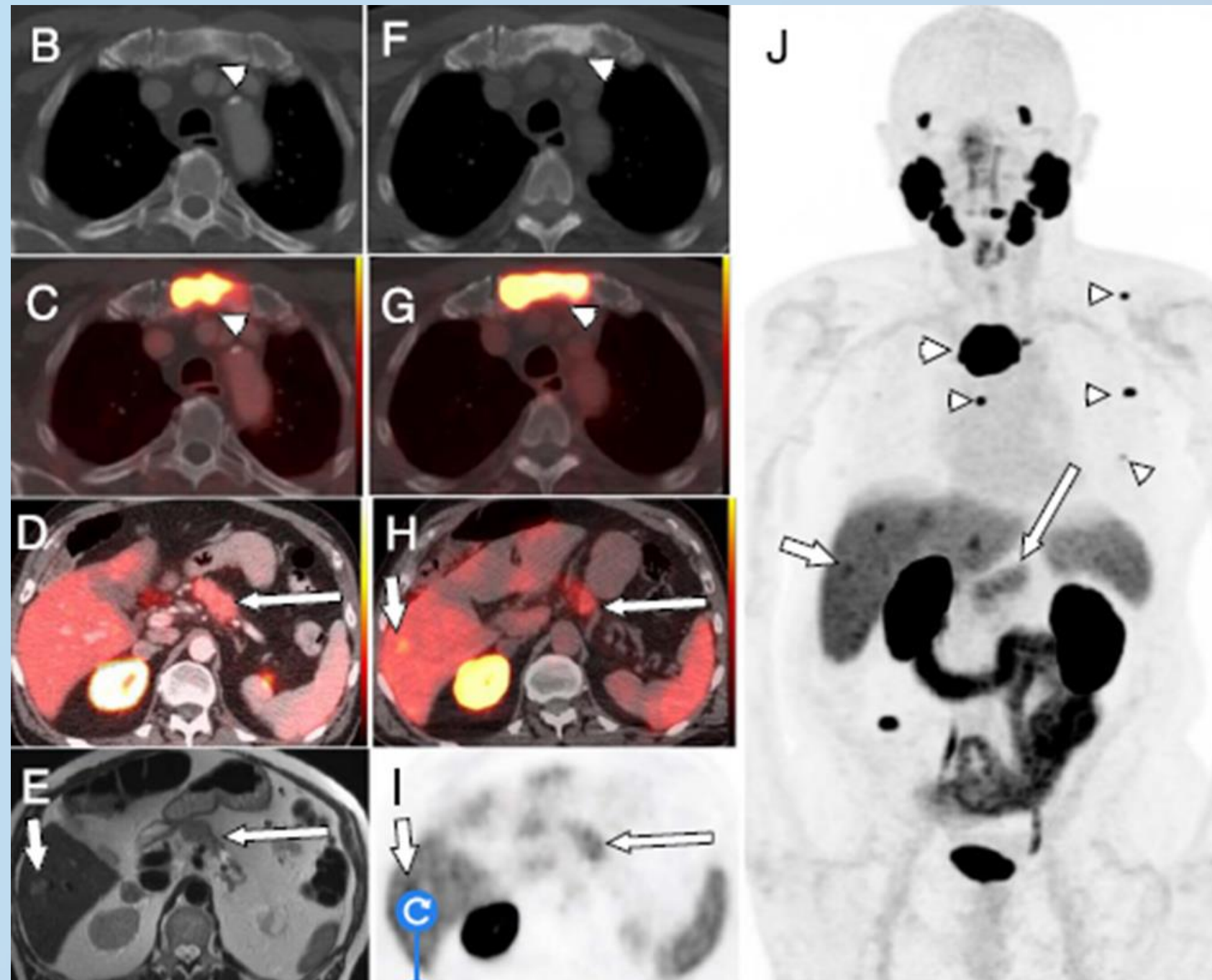
Increased uptake in upper sternum and right iliac bone consistent with bone metastases (small arrowheads)

Increased uptake in the pancreas (big arrowhead)

Management after PET/CT

abiraterone + prednisone

Case report on incidental findings #1



B: axial CT; C and D: fused axial CT; E: axial short T2 image, F: axial CT; G and H: fused axial CT; I: axial PET

Follow-up Piflufolastat (^{18}F) PET/CT 4 months later:

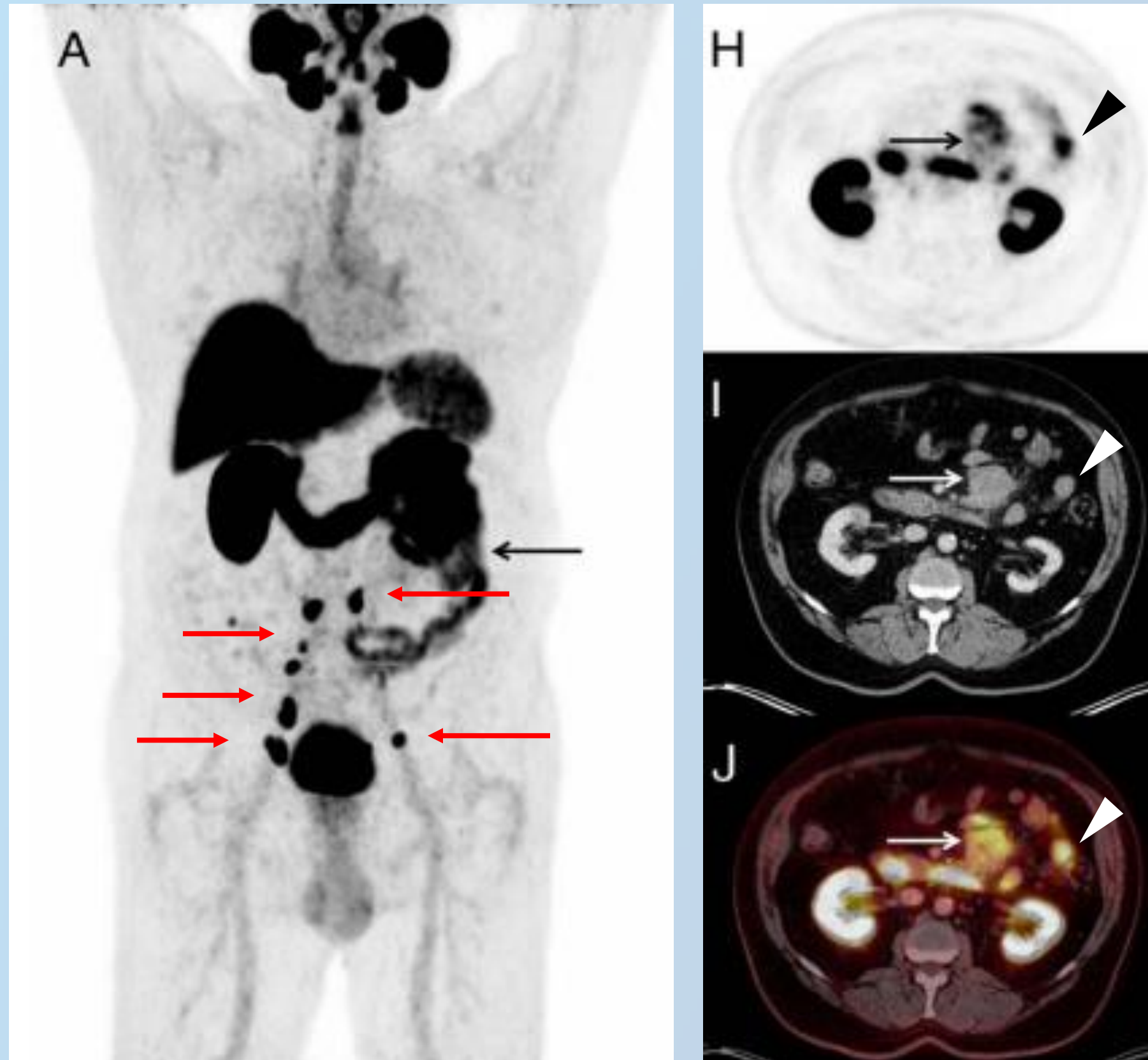
Increased uptake in the sternum, scapula, ribs, and spine (small arrowheads in J).

Increased uptake in the pancreas and liver (big arrowheads).

Liver lesion (short arrowheads in H–J) was biopsied and showed metastasis from a primary pancreatic acinar cell carcinoma.

From Lu Clin Nucl Med 2023

Case report on incidental findings #2



Patient's history

75-year old man

Gleason 9 (5+4), initial PSA 27 ng/mL

Treated with radiation therapy and hormonal therapy with PSA nadir 0.5 ng/mL

Nine years later, biochemical recurrence of prostate cancer with serum PSA level 4.1 ng/mL

Piflufolastat (^{18}F) PET/CT findings

Multiple pelvic and some para-aortic lymph nodes showed highly increased uptake (A, red arrows) suspected for recurrent prostate cancer

Incidental finding of a solid mesenteric mass (A, H, I, J, arrow) and mesenteric lymph nodes (H, I, J, arrowhead) with moderately increased uptake confirmed as low grade follicular lymphoma

5.2

Self testing

Question 1

According to the Summary of Product Characteristics (SmPC), which injected activity of piflufolastat (18) is recommended? (one answer is correct)

A 330 MBq for each patient

B 180 MBq for each patient

C 2 MBq/kg of body weight

D 3-5 MBq/kg of body weight

E 6 MBq/kg of body weight

Question 1

According to the Summary of Product Characteristics (SmPC), which injected activity of piflufolastat (18) is recommended? (one answer is correct)

A 330 MBq for each patient

B 180 MBq for each patient

C 2 MBq/kg of body weight

D 3-5 MBq/kg of body weight

E 6 MBq/kg of body weight

Question 2

Which molecular imaging modality is recommended to assess the efficacy of the treatment? (one answer is correct)

- A** To date, no molecular imaging modality is recommended to assess the efficacy of the treatment
- B** PSMA PET/CT
- C** Fluorocholine PET/CT
- D** Fluciclovine PET/CT
- E** Bone scintigraphy

Question 2

Which molecular imaging modality is recommended to assess the efficacy of the treatment? (one answer is correct)

A To date, no molecular imaging modality is recommended to assess the efficacy of the treatment

B PSMA PET/CT

C Fluorocholine PET/CT

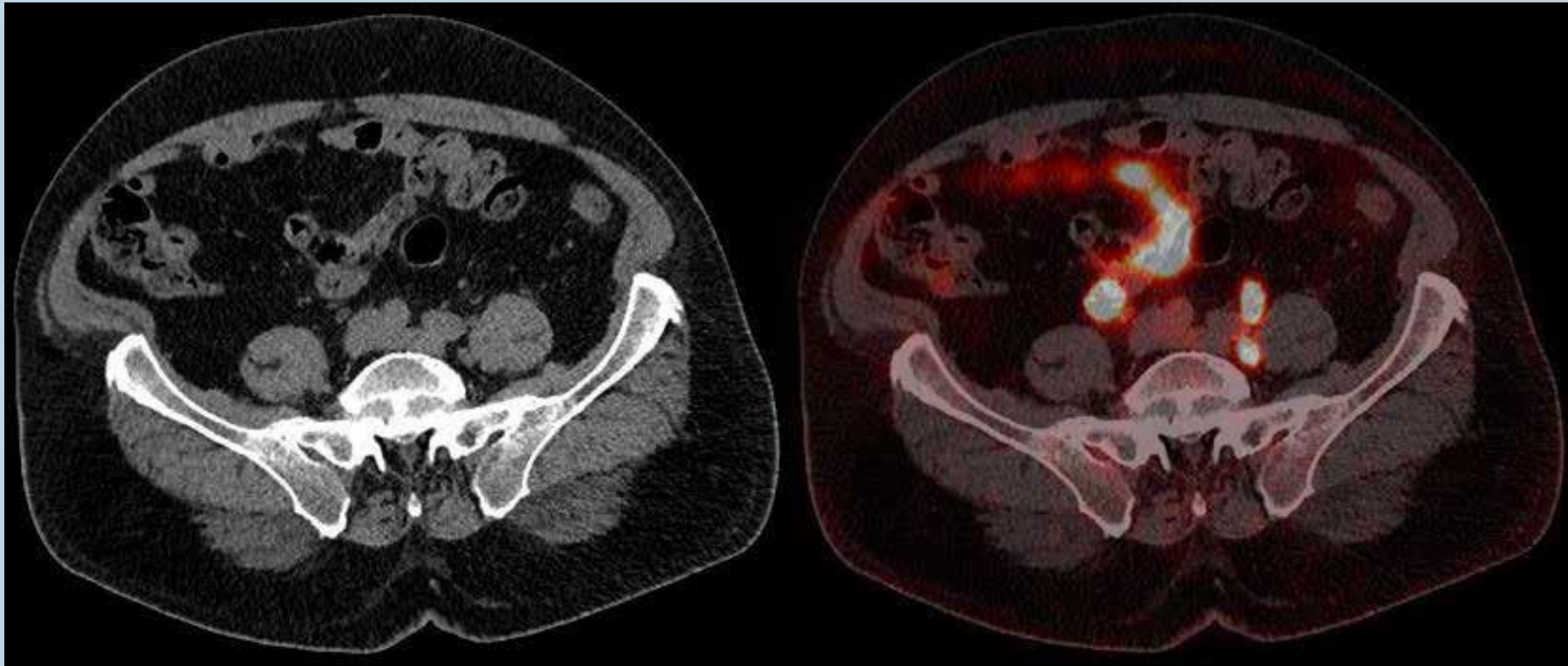
D Fluciclovine PET/CT

E Bone scintigraphy

Question 3

Piflulolastat (^{18}F) PET/CT in a patient with BCR of prostate cancer.

How many foci evocative of recurrent prostate cancer can be seen in this case?



Question 3

How many foci evocative of recurrent prostate cancer can be seen ?

A 4

B 3

C 2

D 1

E 0

Question 3

How many foci evocative of recurrent prostate cancer can be seen?

A 4

B 3

C 2

D 1

E 0

Self testing: Case report on initial staging #1

Patient's history

85-year-old man. | PSA 10.8 ng/ml.

Gleason score 9 (4+5).

MRI: suspicion of prostate cancer with perineural invasion.

CT of the thorax: enlarged mediastinal lymph nodes and lung nodule.

Piflufolastat (¹⁸F) PET/CT findings

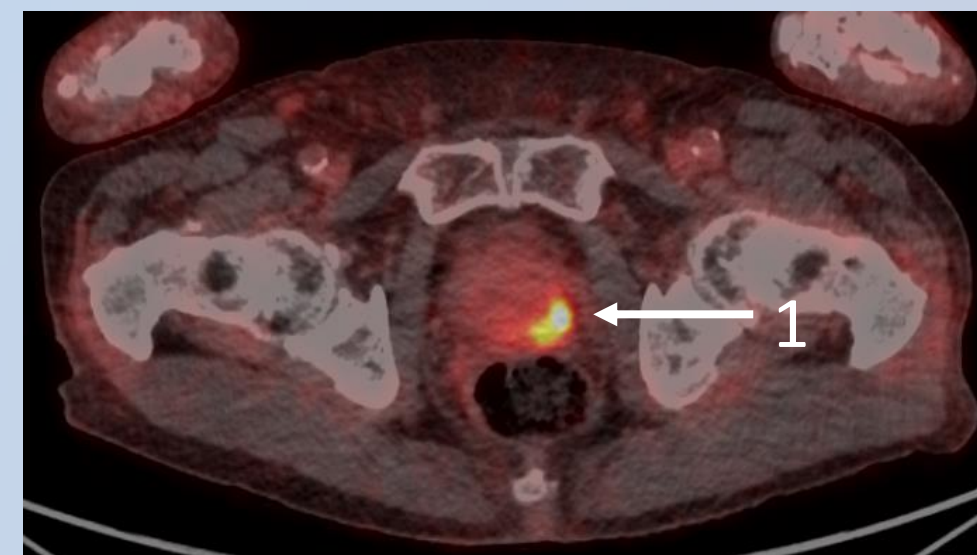
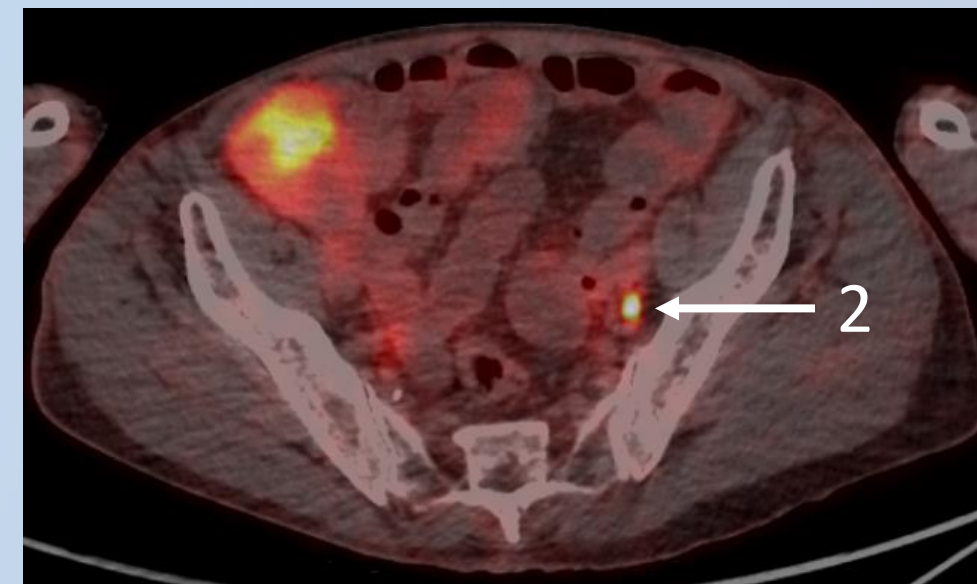
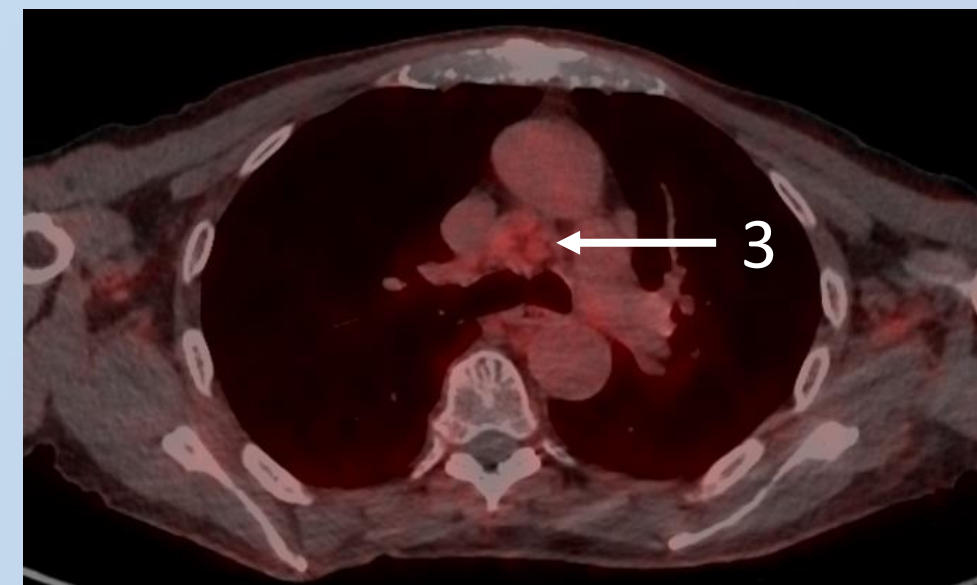
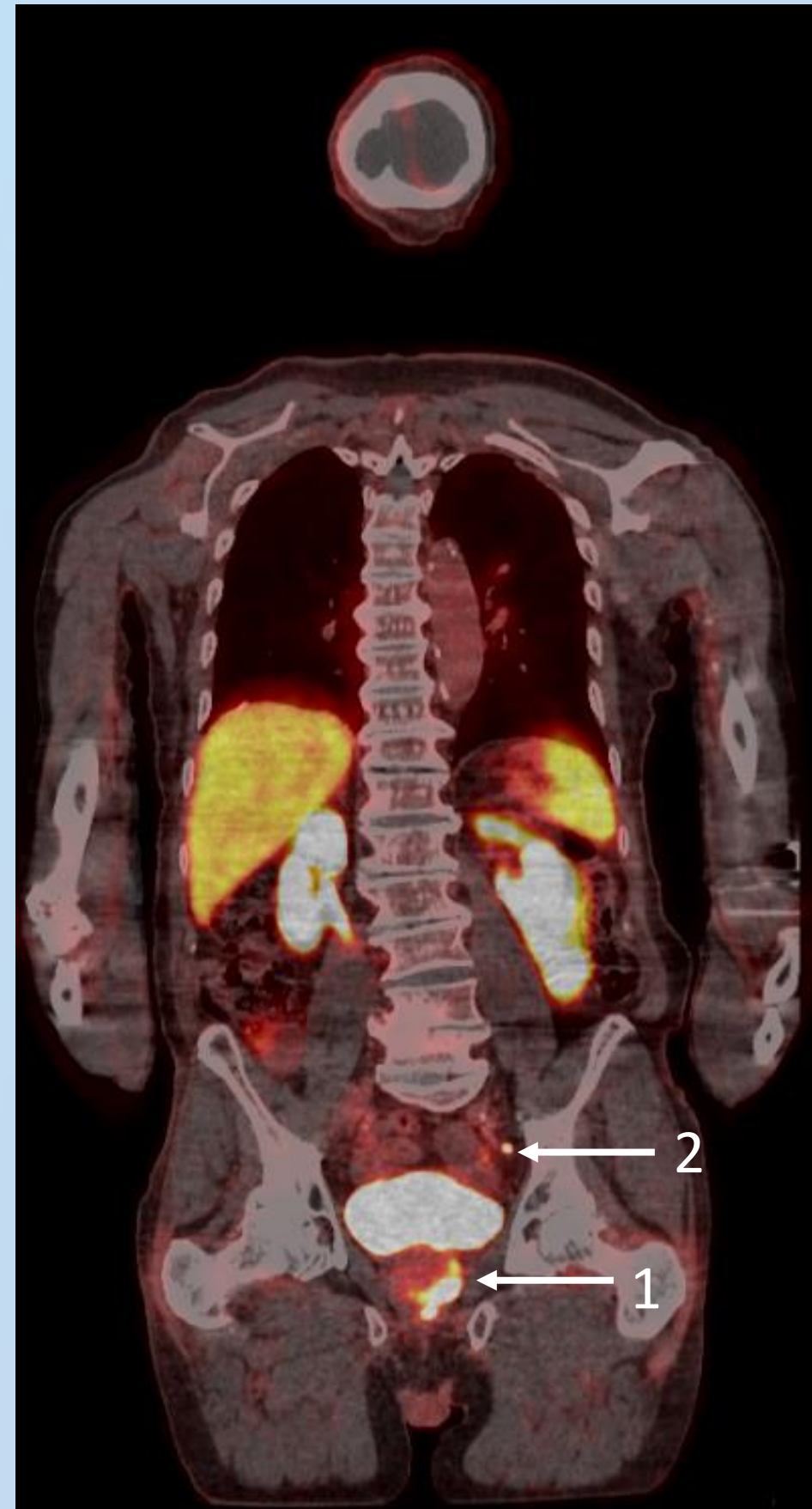
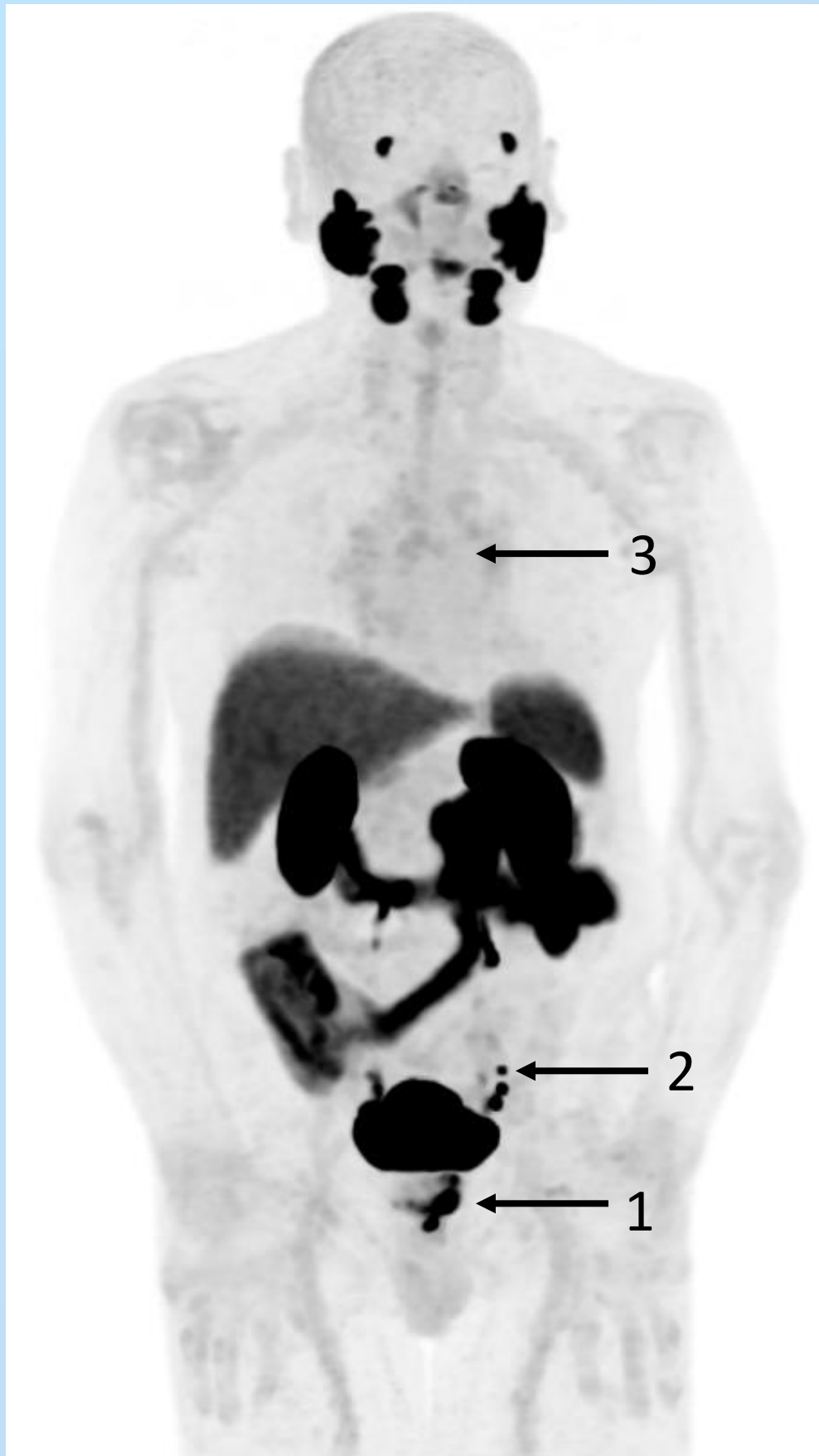Uptake in the prostate, consistent with prostate cancer.

Uptake in the pelvic lymph node, consistent with lymph node metastasis.

Mild uptake in the mediastinal lymph nodes, nonspecific.

No uptake in the pulmonary nodule.

Self testing: Case report on initial staging #1



Piflufolastat (^{18}F) PET/CT findings

1. Uptake in the prostate, consistent with prostate cancer.
2. Uptake in the pelvic lymph node, consistent with lymph node metastasis.
3. Mild uptake in the mediastinal lymph nodes, nonspecific.

Self testing: Case report on initial staging #1

Mild piflufolastat (^{18}F) uptake in the mediastinal lymph nodes is most probably consistent with:

- A** metastasis from prostate cancer
- B** inflammatory changes

Self testing: Case report on initial staging #1

Mild piflufolastat (^{18}F) uptake in the mediastinal lymph nodes is most probably consistent with:

- A** metastasis from prostate cancer
- B** inflammatory changes

Self testing: Case report on initial staging #2

Patient's history

70-year-old man.

PSA 8.7 ng/ml.

Gleason score 8 (4+4).

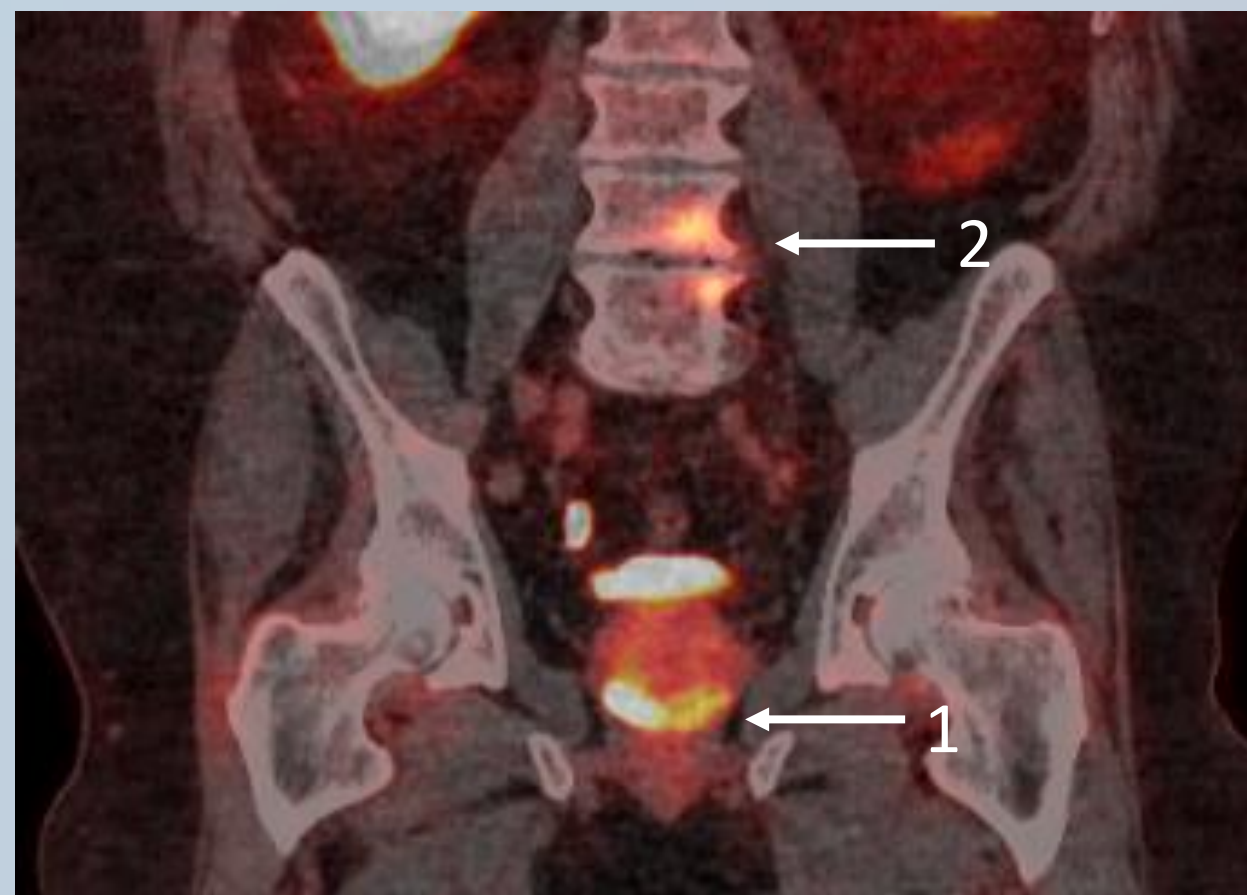
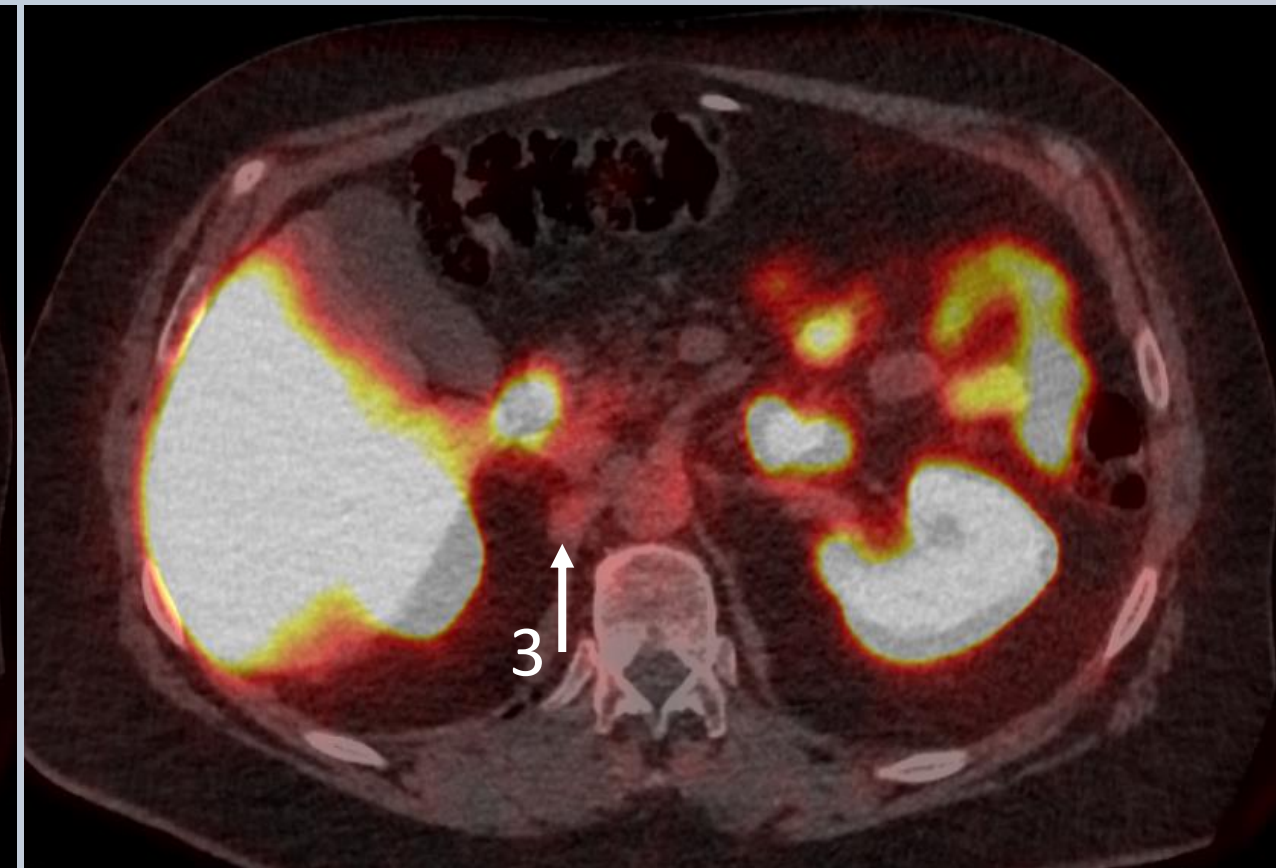
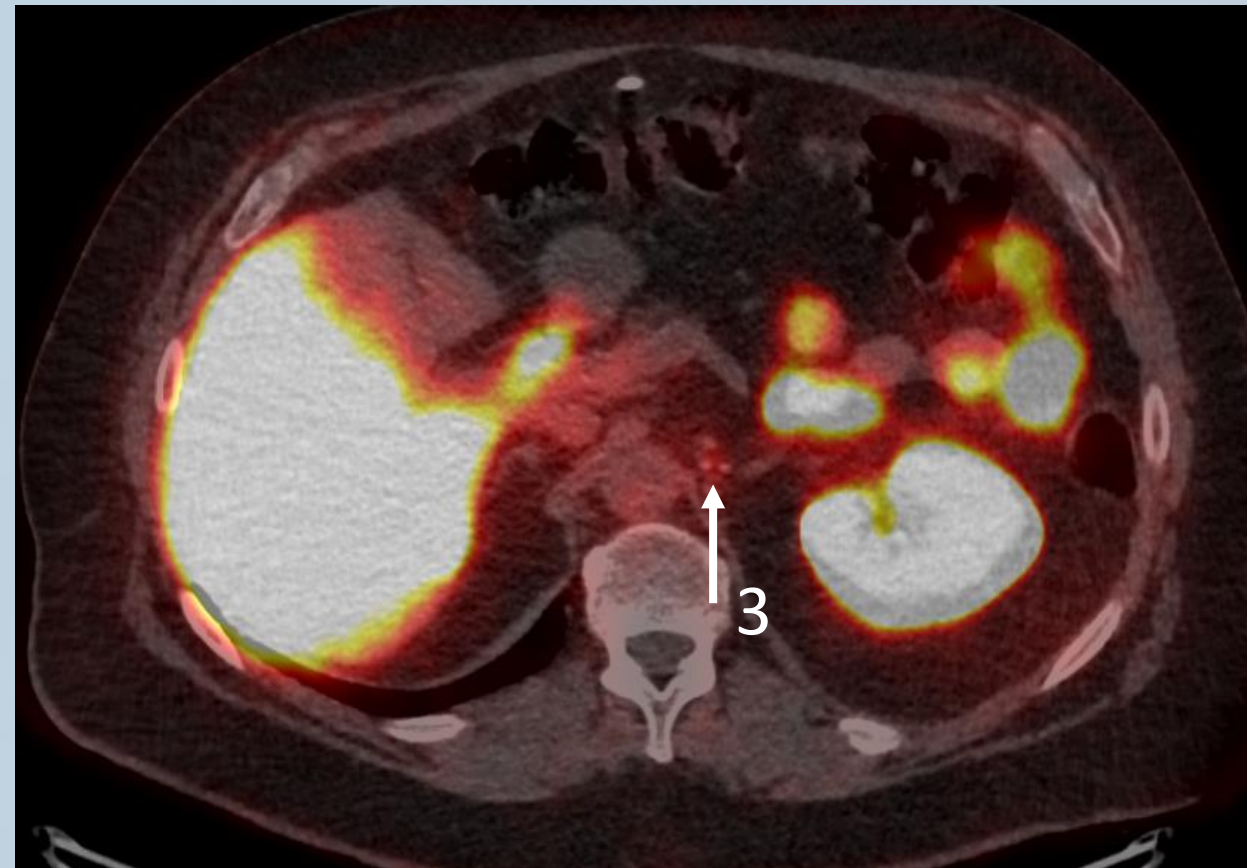
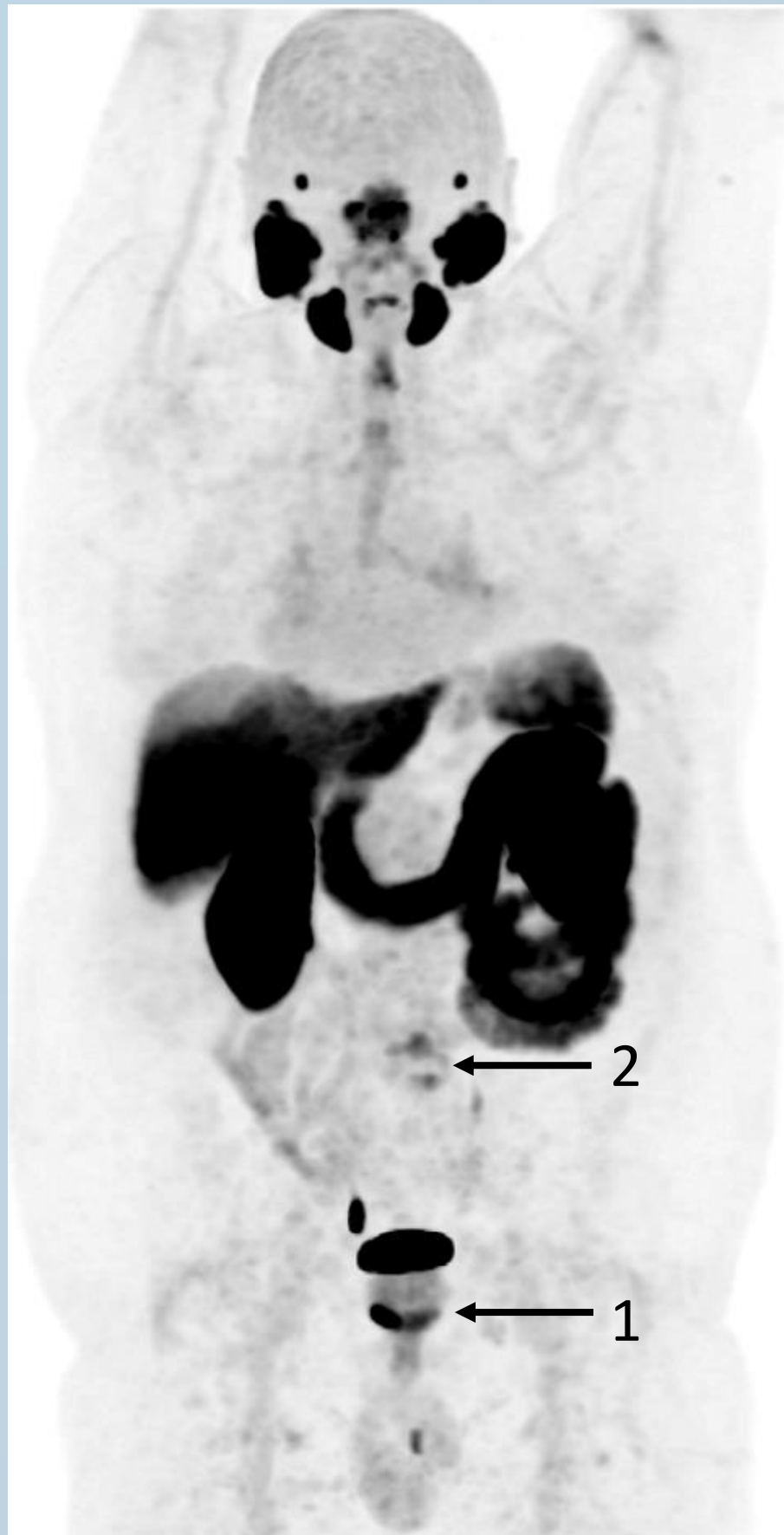Piflufolastat (¹⁸F) PET/CT findings

Uptake in the prostate, consistent with prostate cancer.

Uptake in the lumbar spine, consistent with degenerative changes.

Moderate physiological uptake in ganglia.

Self testing: Case report on initial staging #2



Piflufolastat (^{18}F) PET/CT findings

1. Uptake in the prostate, consistent with prostate cancer.
2. Uptake in the lumbar spine, consistent with degenerative changes.
3. Moderate physiological uptake in ganglia.

Self testing: Case report on initial staging #2

Mild piflufolastat (^{18}F) uptake in ganglia is consistent with:

- A** metastasis from prostate cancer
- B** tuberculosis
- C** physiological findings

Self testing: Case report on initial staging #2

Mild piflufolastat (18F) uptake in ganglia is consistent with:

- A** metastasis from prostate cancer
- B** tuberculosis
- C** physiological findings

Self testing: Case report on BCR #1

Patient's history

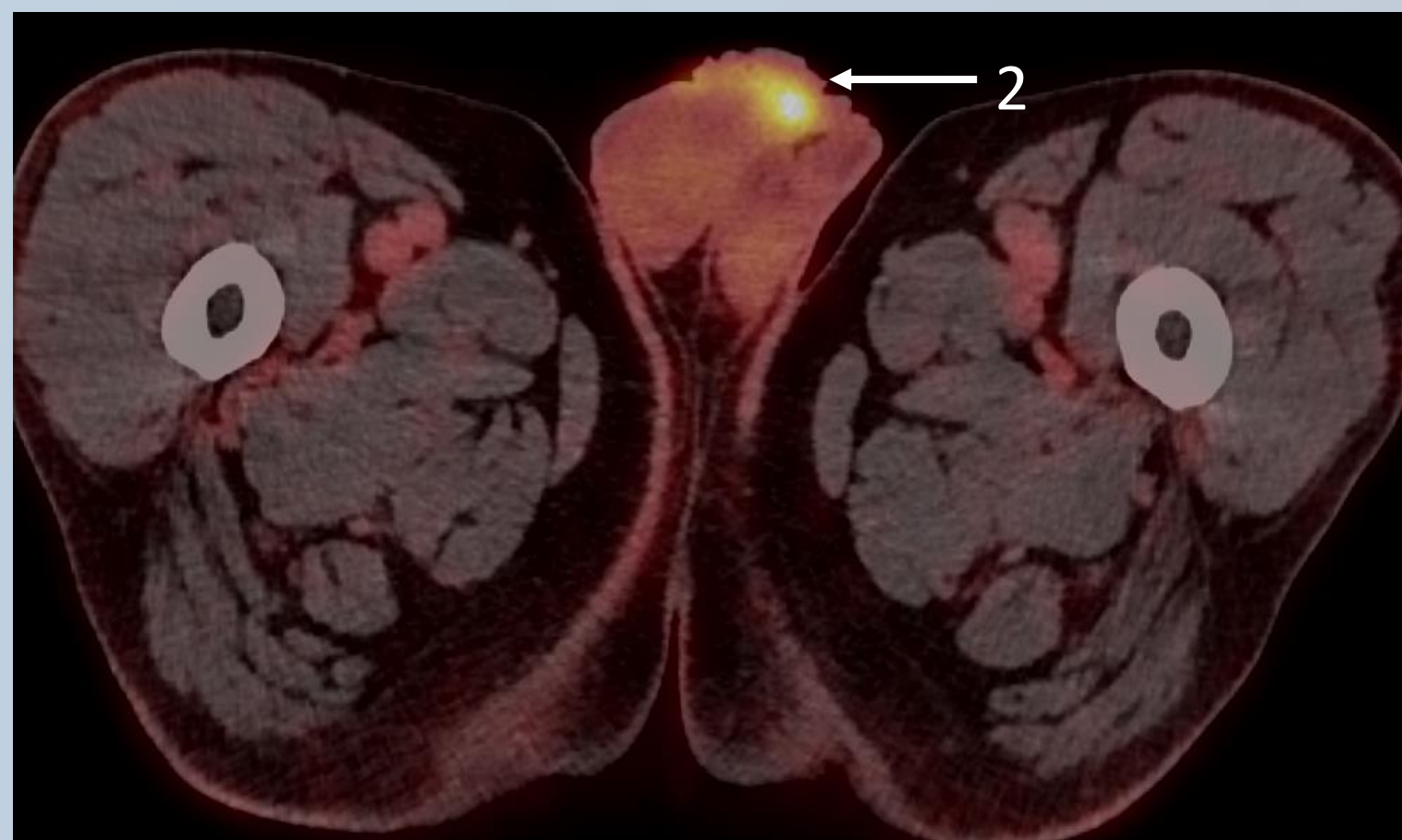
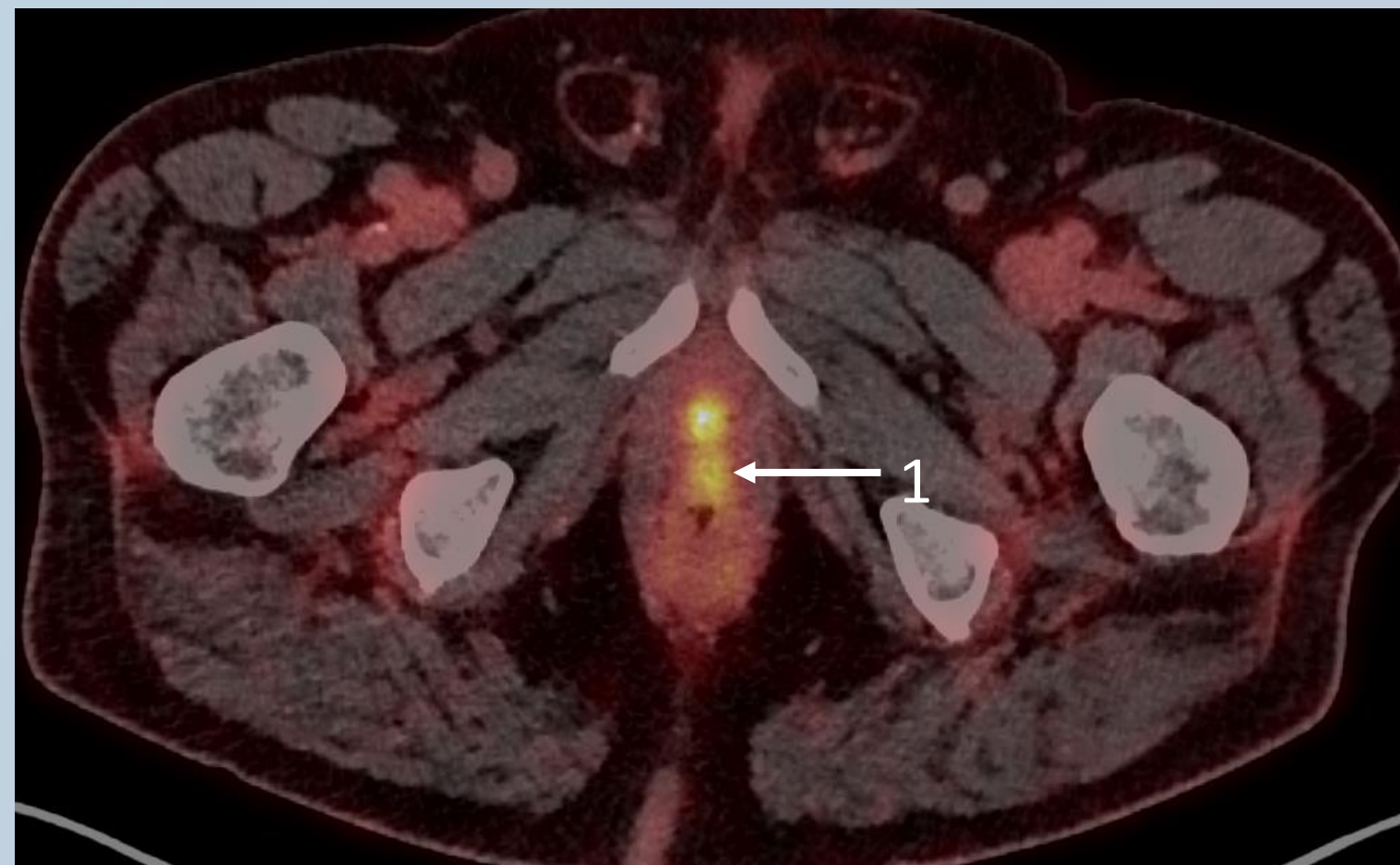
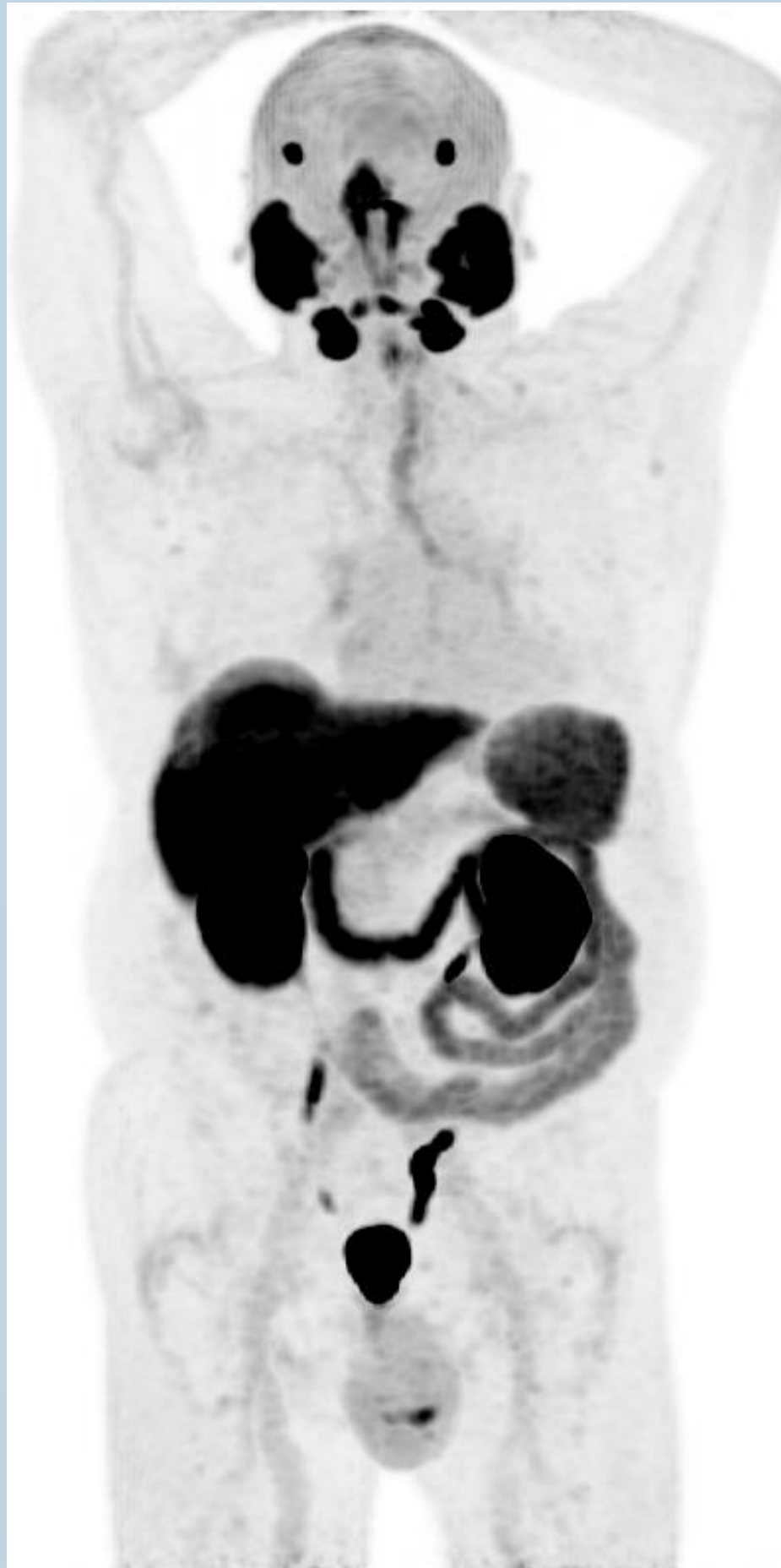73-year-old man.

Gleason score 7 (4+3).

History of RP with ePLND.

PSA 0,59 ng/mL.

Self testing: Case report on BCR #1



Piflufolastat (^{18}F) PET/CT findings

What is your interpretation of the finding 1 and of the finding 2?

Self testing: Case report on BCR #1

What is your interpretation of the finding 1 and of the finding 2?

- A** Recurrent prostate cancer in the prostate bed
- B** Recurrent prostate cancer in the prostate bed and second primary cancer
- C** Recurrent prostate cancer in the prostate bed and urinary contamination
- D** Recurrent prostate cancer in the prostate bed, second primary cancer and urinary contamination

Self testing: Case report on BCR #1

What is your interpretation of the finding 1 and of the finding 2?

- A** Recurrent prostate cancer in the prostate bed
- B** Recurrent prostate cancer in the prostate bed and second primary cancer
- C** Recurrent prostate cancer in the prostate bed and urinary contamination
- D** Recurrent prostate cancer in the prostate bed, second primary cancer and urinary contamination

Self testing: Case report on BCR #2

Patient's history

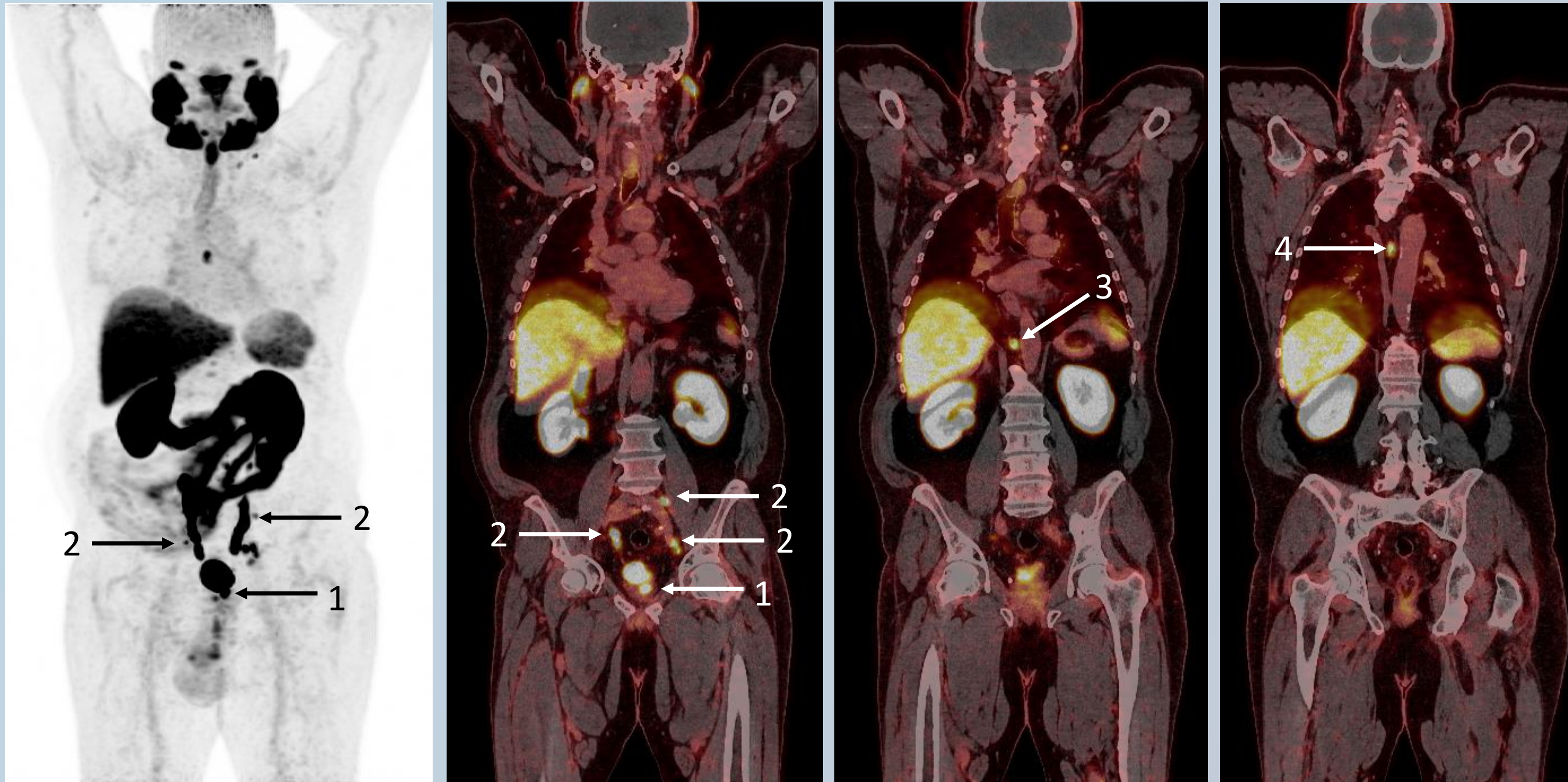
71-year-old man.

Gleason score 8 (4+4).

History of definitive RT of the prostate and the pelvis.

PSA 4,07 ng/mL.

Self testing: Case report on BCR #2



Piflufolastat (^{18}F) PET/CT findings

- Uptake in the
1. prostate
 2. pelvic lymph nodes
 3. paraaortic lymph nodes
 4. supradiaphragmatic lymph nodes

Self testing: Case report on BCR #2

How would you interpret these piflufolastat (^{18}F) PET/CT findings?

- A** Intraprostatic recurrence of prostate cancer
- B** Recurrence of prostate cancer in retroperitoneal and pelvic lymph nodes
- C** Recurrence of prostate cancer in supradiaphragmatic lymph nodes
- D** None of above
- E** A+B+C

Self testing: Case report on BCR #2

How would you interpret these piflufolastat (^{18}F) PET/CT findings?

- A** Intraprostatic recurrence of prostate cancer
- B** Recurrence of prostate cancer in retroperitoneal and pelvic lymph nodes
- C** Recurrence of prostate cancer in supradiaphragmatic lymph nodes
- D** None of above
- E** A+B+C

Self testing: Case report on BCR #3

Patient's history

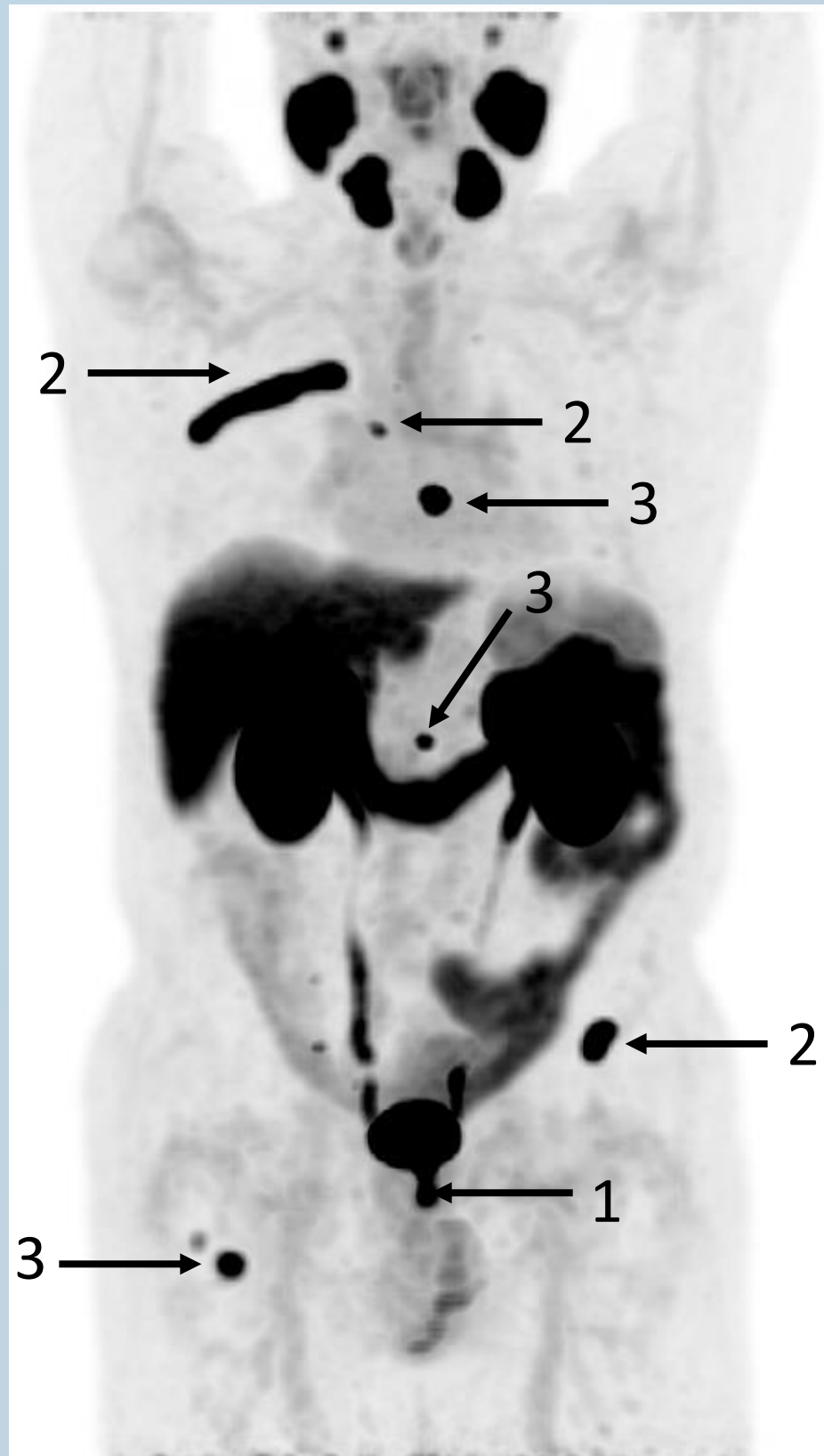79-year-old man.

Gleason score 9 (5+4).

History of definitive RT of the prostate and the pelvis.

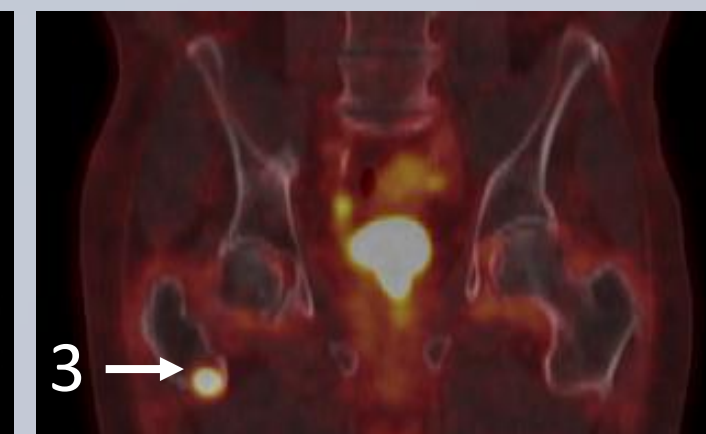
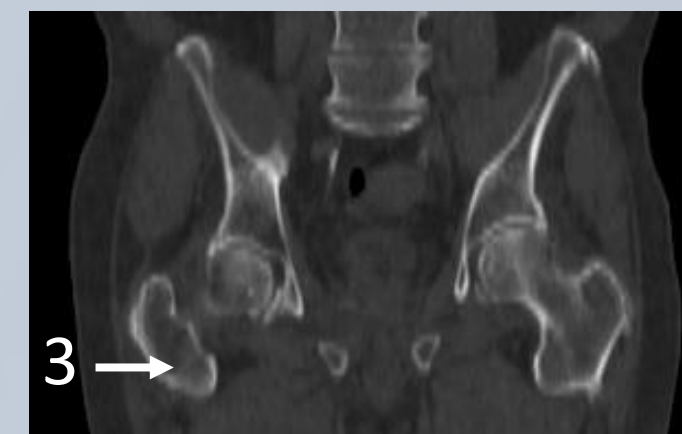
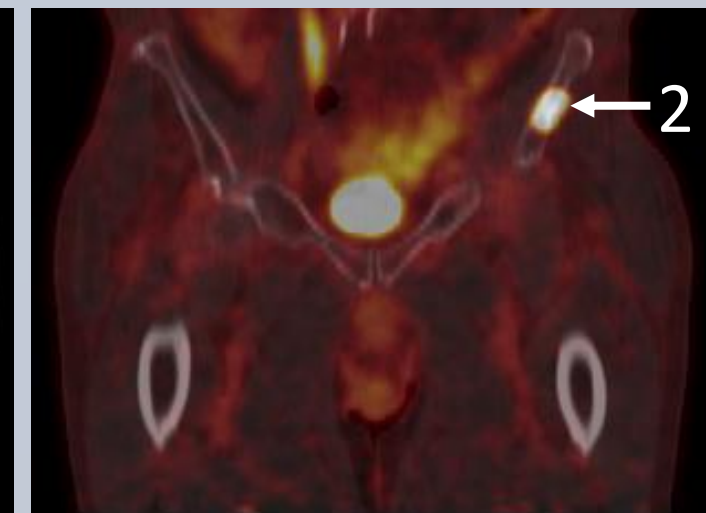
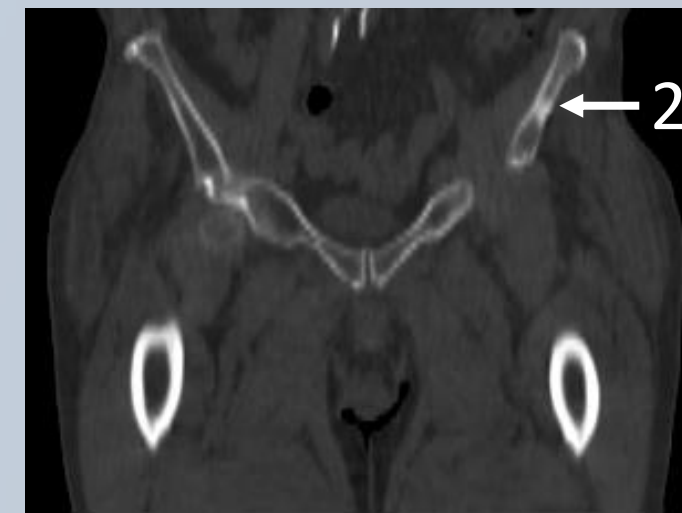
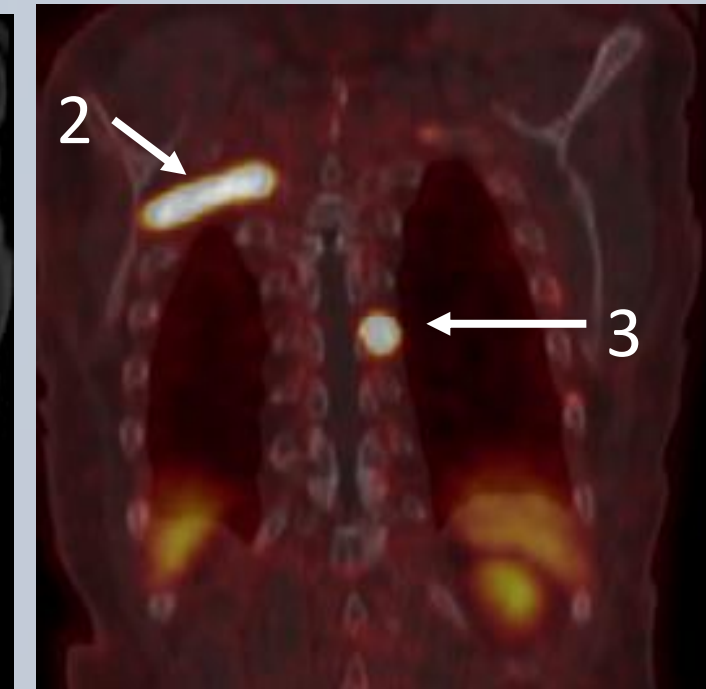
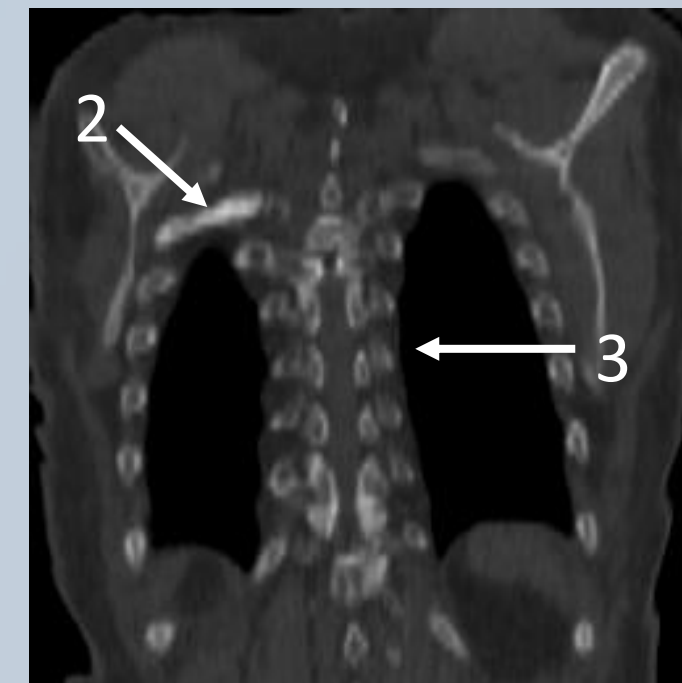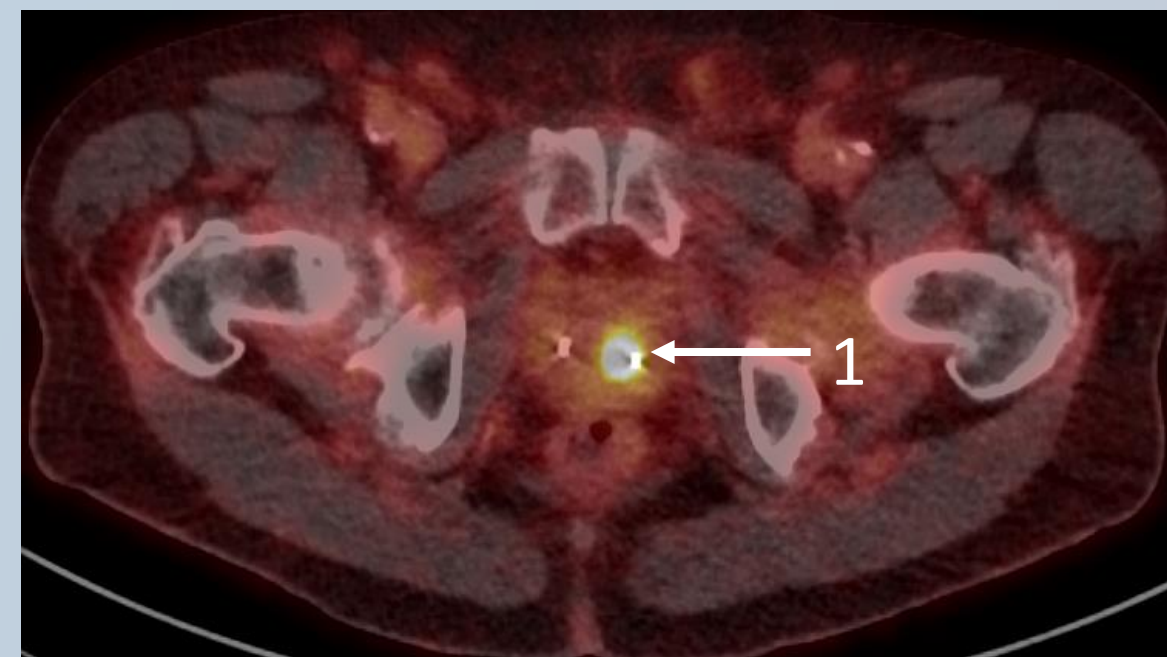
PSA 6,4 ng/mL.

Self testing: Case report on BCR #3



Piflufolastat (^{18}F) PET/CT findings

1. Uptake in the prostate
2. Several uptakes in the skeleton,
3. Some of the areas of increased tracer uptake in the bones seen on PET, have no corresponding lesions on the CT



Self testing: Case report on BCR #3

How would you interpret these piflufolastat (^{18}F) PET/CT findings?

- A** Intraprostatic recurrence of prostate cancer
- B** Recurrence of prostate cancer in the right femur and in the vertebral column
- C** Recurrence of prostate cancer in the rib and in the pelvis
- D** None of above
- E** A+B+C

Self testing: Case report on BCR #3

How would you interpret these piflufolastat (^{18}F) PET/CT findings?

- A** Intraprostatic recurrence of prostate cancer
- B** Recurrence of prostate cancer in the right femur and in the vertebral column
- C** Recurrence of prostate cancer in the rib and in the pelvis
- D** None of above
- E** A+B+C

Your training is now complete
Thank you for your attention.